



Computer Engineering Complete Dentures Workflow: Systematic Techniques Review

**Mohammed M. Al Moaleem^{a*}, Omaima A. Al-layl^b, Manar A. Alhomood^b,
Walaa A. Ageeli^b, Alzhouor A. Qsadi^b, Tahani I. M. Mohammed^b,
Emtinan S. Baraqt^b, Bashayr M. A. Zubayni^b, Nada I. Alalmaie^b
and Ahmed H. M. Huraysi^c**

^a *Department of Prosthetic Dental Science, College of Dentistry, Jazan University, Jazan 45142, Saudi Arabia.*

^b *Dental Intern, College of Dentistry, Jazan University, Jazan, Saudi Arabia.*

^c *General Practitioner, Private Clinic, Jazan, Saudi Arabia.*

Authors' contributions

This work was carried out in collaboration among all authors. All authors read and approved the final manuscript.

Article Information

DOI: 10.9734/JPRI/2021/v33i53A33653

Editor(s):

(1) Dr. Aurora Martínez Romero, Juarez University, Mexico.

Reviewers:

(1) Mohammed Shammam, Ibn Sina National College for Medical Studies, Saudi Arabia.

(2) Mudher Abdulmunem Abduljabbar Ali, URUK University, Iraq.

Complete Peer review History, details of the editor(s), Reviewers and additional Reviewers are available here:

<https://www.sdiarticle5.com/review-history/78337>

Review Article

Received 29 September 2021

Accepted 03 December 2021

Published 04 December 2021

ABSTRACT

Background: The progress in the use of computer-aided design/computer aided manufacturing (CAD/CAM) to fabricate removable prosthodontic prostheses in dental clinics has been exponential. Commercially existing CAD/CAM denture techniques grow every year with increasing benefits to dentists and patients.

Study Design: Systematic review.

Aims: This review assessed and evaluated the different clinical production protocols of presently accessible CAD/CAM denture systems that offer decision support for dental practitioners.

Methodology: Data for the current object were collected by surveys from different companies manufacturing the Computer Engineering Complete Denture (CECDs). All related subjects published at the last 10 years were collected and included in this review. Techniques were arranged in alphabetical order, as follows. AvaDent Digital Dentures (Global Dental Science), Baltic

Denture Creator System (Merz Dental GmbH), and Ceramill Full Denture System (Amann Girrbach AG) can manufacture denture fabrication in three visits, including a try-in step. DENTCA Digital Dentures (Whole You Nexteeth, Inc) can also perform this in three visits. The Wieland Digital Denture (Ivoclar Vivadent, Inc) can manufacture in four dental appointments. Recently developed VITA VIONIC Digital System (VITA Zahnfabrik, Bad Säckingen, Germany) can perform two-step CECD manufacturing.

Results: Most of the systems involved subtractive manufacturing for the fabrication of their dentures and only closed systems. However, Baltic Denture System and VITA VIONIC material types are an open structure that allow users to choose among different handling protocols. It can be shared with several unclosed digital scanner, CAD software options, and milling machines.

Conclusions: The six existing CECD fabrication systems offer many advantages. The decision on which technique to use may be contingent on the dentist's prosthodontic expertise, patient output amount, and requirements concerning denture individualization.

Keywords: Digital denture; Milling; CAD-CAM; complete engineering denture.

1. INTRODUCTION

In computer-aided design/computer-assisted manufacture (CAD/CAM), a 3D object is designed using computer software and made-up through a fully automated procedure [1]. CAD/CAM has been used in dentistry since the mid of early 1980s, especially for fixed prosthodontic prostheses, such as crowns or bridges and implant abutments and maxillofacial prosthetic device [1,2].

Patient dissatisfaction, insufficient retention, and inadequate aesthetics were the most common difficulties associated with CECDs. The addition of a trial placement option for CECDs could result in an improved clinical outcome, thereby minimizing the incidence of other complications related to occlusal vertical dimension (OVD), centric relationship, tooth setup, and aesthetics, thereby enhancing patient pleasure and reducing the amount of remakes. The trouble in interpretation the digital performance for an objective calculation earlier to fabricate is a unique complication for CECDs [2,3].

CECD construction offers significant advantages over the conventional processing system described by Kattadiyil 2017, such as minimizing the appointments visits, fitting improvement, and/or retention [4,5,6] and automatic filling [2]. Kattadiyil et al. reported two CECD constructors that used condensed appointment protocols to engineer prostheses and considered these protocols as significantly advantageous [2,3].

For removable dentures, CAD/CAM fabrication is a novelty [1,7,8,9]. The prosthesis device base is milled from ready made acrylic resin blocks [6]

that were previously polymerized under high heat and pressure. The result is a highly condensed resin that is assumed to release less irritating monomer [10] and to have low numbers of microporosities. Porosities are among the factors measured for the microbial colonization of the denture device base [11], which is often high, particularly among elder ages or dependent patients [12].

The presented CAD/CAM denture assembly techniques provide several returns. The reduced session protocols appeal to dentists and patients and make full-teeth denture device prosthodontics attractive even to young dentists. The choice of which technique to use should depend on the dentist's prosthodontic expertise, requirements for denture individualization, and throughput rate. Although the initial scientific evidence supports the clinical superiority of CECD-made-up full-teeth dentures, evidence regarding material-specific possessions is still scarce [13-16].

This review aims to comparability the clinical and laboratory protocols of the currently available CAD/CAM full-teeth denture structures' workflow for the fabrication of CDs. The results will give an overview of the different clinical denture adaptation protocols and deliver choice support for dental physicians.

2. AVAILABLE CECD SYSTEMS

Although many digital systems have been proposed for digital and milled full-teeth denture construction, the precise digital duplication of an edentulous arch in its functional and dynamic forms with an accurate both-arch relation remains challenging [17,18]. Currently, six

systems offered by manufacturing companies are available for the production of CECDs; these are arranged alphabetically [13-14] as follows:

1. AvaDent Digital Dentures (Global Dental Science),
2. Baltic Denture Creator System (Merz Dental GmbH),
3. Ceramill Full Denture System (Amann Girrbach AG),
4. DENTCA Digital Dentures (Whole You Nexteeth; DENTCA, Inc; Whole You, Inc),
5. Wieland Digital Denture (Ivoclar Vivadent, Inc),
6. VITA VIONIC Digital System (VITA Zahnfabrik, Bad Säckingen, Germany).

1. AvaDent Digital Denture

Overview: AvaDent uses subtractive manufacturing to fabricate dentures. They offer two types of full-teeth dentures, as follows: milled denture base with bonded teeth; and one-set monolithic prosthesis. These are produced by AvaDent (Global Dental Science

Europe BV Inc). The fabrication needs two appointments if a try-in visit to assess aesthetics, phonetics, and function is not involved. The high-translucency enamel and dentin core give the great natural aesthetics. The other type of prosthesis offers a milled denture base with bonded denture full-setup of teeth. AvaDent device can provide the clinician with immediate CDs, dentures for maxillary or mandibular arch, record bases, radiographic directors, conversion prostheses, confirmation jigs, and definitive hybrid fixed implant prostheses [13,14].

Manufacturing Appointments: AvaDent dentures can be done in two appointments. If the clinician feels more comfortable gathering a try-in denture to evaluate aesthetics, phonetics, and purpose of the digital CDs can be completed in three dental visits. This system included the use of Anatomic Measuring Device (AMD), which is utilized for archs relation records [3,10,13,19-21]. Fig. 1 shows case manufactured with AvaDent trays and AMD for CD making. Fig. 2 show routine of optical scanning for partial dental arches. Fig. 3 described the use of present dentures of patients as trays.

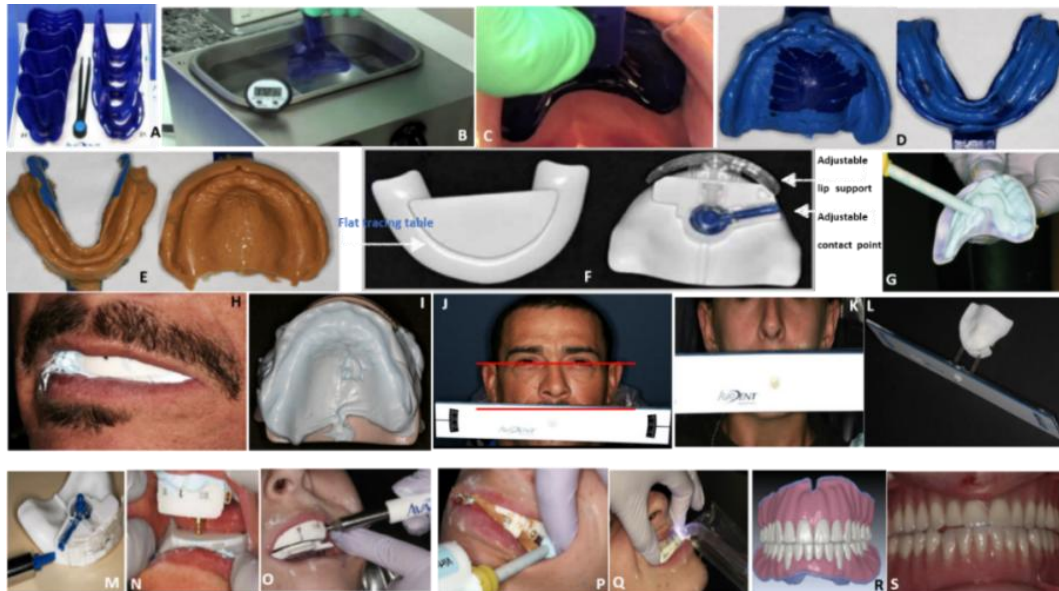


Fig. 1. Thermoplastic trays in different sizes (A-C); Maxillary and Mandibular definitive Impressions with PVS (D-E). Maxillomandibular registration material placed in AMD maxillary tray (F-G). Registration of interpupillary line, the contact point is adjusted up and down using a screwdriver to establish appropriate OVD (F-L). Adjustment of the VDO using the wrench to raise or lower the pin (M-P), stabilize transparent guide (Q), Digital preview of virtual arrangement of denture during try-in (R), and final intraoral CECDs in patient mouth (S). (Kattadiyil et al., 2013; Infante and Yilmaz., 2014, Steinmass et al., 2017, Contrepolis et al., 2018; Goodacre, et al., 2018; Srinivasan et al 2019)

First appointment includes separate definitive upper and lower impressions, which are completed using supplied trays (AvaDent) after thermoplastic adaptation (A–C). Border-molded and definitive impressions are made from heavy-consistency polyvinyl siloxane (D–E). Anatomic Measuring Device (AMD) is employed for jaw relation records (F). The AMD consists of lower partial arch tray with a flat tracing table and an upper partial arch tray with a centrally adjustable Gothic arch copying and adjustable lip support flange (G–I). Correct AMD was designated and covered with specified adhesive. The AvaDent orientation ruler is involved to align the upper AMD to the patient’s interpupillary line. The patient is asked to close his mouth until the contact point of the upper AMD and the tracing table of the lower AMD is reached (J–N). The pattern obtained resembles an arrow. Inter-occlusal recording material is inserted between the upper and lower AMDs. Composite resin is used to stabilize a translucent guide to create

midline, gingival display, and incisal edge location (O–Q). The AMDs and the definitive impressions are shipped to AvaDent. Digital preview and approval by dentist prior to milling of final full-set CDs (R).

Second appointment/optional includes try-in denture stage (ATI). This has a milled base with sockets hooked on which denture teeth are held with wax. In this clinic time, denture teeth can be adjusted (if needed) by rearrangement them in trial denture wax.

Third appointment. The CECD delivery is almost identical to the insertion of a conventionally fabricated CD (S). Pressure pointer adhesive or fit inspector is used. Occlusal modification might be important and can be accomplished at the same visit. Severe disparity in occlusal interactions between the dentures can be accustomed next to the clinical remount method [13,14].

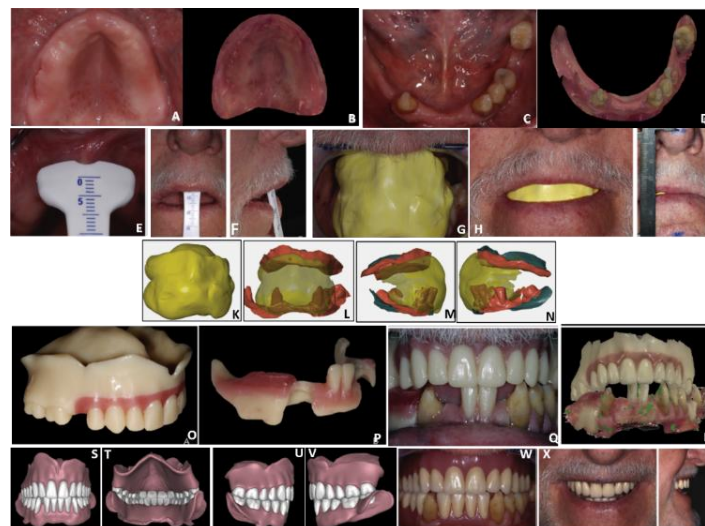


Fig. 2. Optical scans of edentulous maxilla (A-B), partially edentulous mandible (C-D). Registering lip length with Papilla-meter (AvaDent; Global Dental Science Europe BV), Positioning of Papilla-meter for measuring lip length while maintaining lip in relaxed state (E), Lateral view showing positioning of Papilla-meter to maintain labial support (F). Jaw relations by a ball of polyvinyl siloxane putty placed between jaws, patient instructed to close gently (G), Lips molded gently to establish approximate lip support and fullness (H), Establishing arbitrary approximate vertical dimension of occlusion (I), Aligning optical scans with scan of putty block record, Frontal view, right lateral view, Left lateral view of aligned scans (K-M), Definitive jaw relation with record bases (N). Maxillary with tooth arrangement in wax to first premolars with milled molar (O), Mandibular with central incisors and posterior occlusal wax blocks (P), Centric relation (Q), Optical scan of WTIs in centric relation to register definitive jaw relation (R), Digital preview showing virtual tooth arrangement, Frontal view, Posterior view, Right lateral view, Left lateral view (S-V), CAD-CAM milled CDs intraoral retracted frontal view of inserted dentures (W), Frontal view of smile with dentures in place and profile view of smile with dentures in place (X). (Steinmass et al., 2017; Srinivasan et al. 2019)

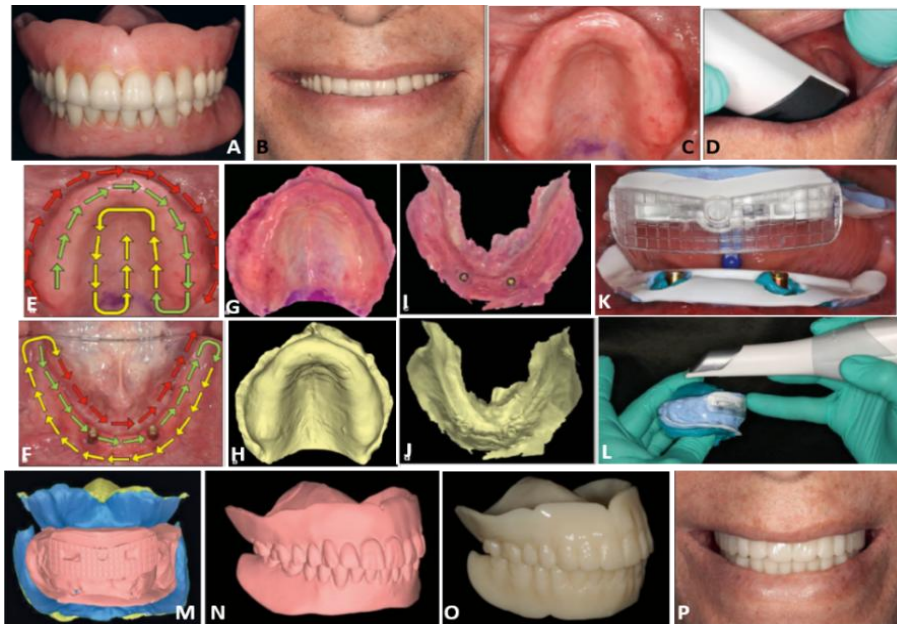


Fig. 3. Patient's existing denture fabricated 15 years ago (A), Pretreatment smile (B), Occlusal view of the maxilla (C), Finger retraction of cheeks to determine vestibular depth (D), Suggested scanning pathway for maxillary arch (E), Suggested scanning pathway for mandibular arch (F), Intraoral scan of maxillary arch in color (G), Maxillary scan without color. (H), Scan of mandibular arch in color (I), Mandibular scan without color (J), Gothic arch-tracing device (K), Intraoral scan of gothic arch-tracing device (L), Digital mounting of intraoral impressions using interocclusal record (M), Intraoral scan of denture (N). CAD/CAM esthetic try-in denture (O), Intra-oral CAD/CAM-milled monolithic definitive denture (P). (Infante et al., 2014; Goodacre et al., 2018, Srinivasan et al., 2019)

2. Baltic Denture System

Overview: The designed Baltic Denture System (BDS) is for correcting bite rims or occlusal rims containing preformed occlusal arches (BD Keys Set Component, Merz Dental GmbH). It uses subtractive manufacturing for the construction of CDs. Figs. 4A and B show that relining is performed until the dental arches are positioned in the anatomically accurate 3D position with two clinical visits [13-14,22].

Construction Steps: The existence of teeth on the different dimensions trays (Fig. 4C) permits evaluation of the overall aesthetics, lip support, interocclusal space, and tooth placement. The BD-KEY trays identically replicate the form or outline and size of the denture teeth in the milling blocks; thus, these trays serve as try-in dentures to confirm the patient's approval of the future CDs. BDS protocol composed of an adjustment clinic and the denture insertion visit. Baltic Denture Creator System is produced by Merz Dental GmbH.

Firstly, the vertical occlusal dimension (VOD) is measured. Then, a functional impression is prepared. The trays are adjusted intraorally. Afterward, by supporting the BD upper Key (a bite rim resembling the master upper dental set) with silicone impression material or thermoplastic impression compound, the occlusal level, incisor dimension, and lip support are recorded. When the upper MXDA has been accustomed to the proper position, the BD lower Key (a bite rim approximating the ultimate MUDA) is joined with the BD upper Key by click maneuver and again reinforced with silicone impression material to reach the earlier determined VD and the CR. The BD Keys resemble the final upper and lower arches. The adjusted keys also serve as try-in dentures, so that the final CDs can be placed at the next dental visit (Fig. 4D).

Next, following the milling of the CD, the insertion is the same as to that of any conventional CD. Occlusal modification can be achieved intraorally or by using a clinical remount step. Otherwise, the usual impression trays are used, and then, the outstanding steps are digitized (Figs. 4A2-G2). [13,14,22].

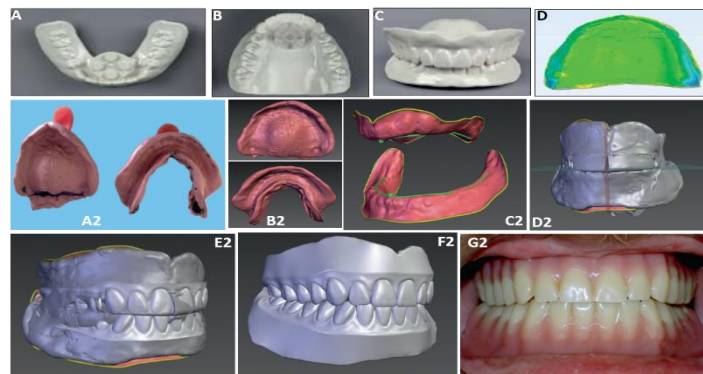


Fig. 4. Mandibular BD Key (A), Maxillary BD Key (B), and both keys click-fixed together (C), High congruence between milled CAD/CAM denture base and master cast. Green = maximal concordance; turquoise and yellow = less concordance. Maxillary and mandibular definitive impressions (Figure 4A2), Stereolithography (STL) files after importing into software, Maxillary and Mandibular (Figure 4B2), Denture boundary line created by setting path points to form line (Figure 4C2), Occlusal rim, occlusal plane, and midline incorporated into image in software (Figure 4D2), Alignment of dental arches according to occlusal rims (Figure 4E2), Digital preview of virtual arrangement (Figure 4F2), Intraoral frontal view of definitive maxillary and mandibular CDs (Figure 4G2) (Yilmaz et al., 2016).

3. Ceramill Full Denture System

Overview: The Ceramill denture system is parallel to the AvaDent digital system. It is two-visit structure and industrial by Amann Girrbach (AG), Germany. It uses subtractive manufacturing for the construction of upper or lower CDs [13, 23-24].

Manufacturing visits: First visit. The existing CDs are used as custom trays to record the final impression of the edentulous arches via the closed mouth system by means of a light-body VPS material. The patient is educated to make functional movements of the mouth to registered a dynamic impression of the buccal and lingual vestibule (Fig. 5A). Then, the upper and lower are detached from the patient's mouth after complete setting of the impression material. The dentures are digitized with an intraoral scanner. In this step, all the denture surfaces, including the impression, intaglio, and cameo surfaces, are recorded digitally. The scanning of the upper impression starts at the distobuccal area on one side and passages toward the anterior area, the soft palatal areas, and finally, the distobuccal area on the opposite (Fig. 5B). For lower impression, scanning includes moving the scanner head in a slow zigzag manner, beginning at the distal area on one side and following the ridge crest to the other side (Fig. 5B). The dentures are placed back in the patient's mouth, and their stability is ensured (Fig. 5C). Next, the CR is documented with an

intraoral scanner. At the end of this appointment, the alignment function of the scanning software is used to automatically align the two digitized denture images to CR by means of the bite scan area (Fig. 5D) [13,14, 22-24].

At the laboratory, the scanned upper and lower denture duplicate format is saved and transferred to a 3D image control computer software program. The entire scan image is segmented into three parts, namely, the upper impression, the lower impression, and the dentition portions. These parts are saved separately in the software format. Subsequently, the digital impressions of the intaglio surface of the denture are inverted to create a digital model of the upper and lower arches by using the software. In this stage, the digital models of the edentulous arches are digitally constructed in the correct inter-arch jaw relationship and are ready to be used for designing the denture (Figs. 5D–E). The digital upper and lower edentulous arches, as well as the dentition part, are transferred into a dental design software to design the denture base and arrange the artificial teeth for the new CD (Fig. 3F). The design includes arrangements of the teeth on the existing arches in CR. Lastly, the setting up of teeth are completed.

Second visit. The prostheses (CDs) are seated into patient's mouth subsequent the intra-oral alteration of occlusion (Fig. 5G). Another case is presented in Figs. 52A–2S [23-24].

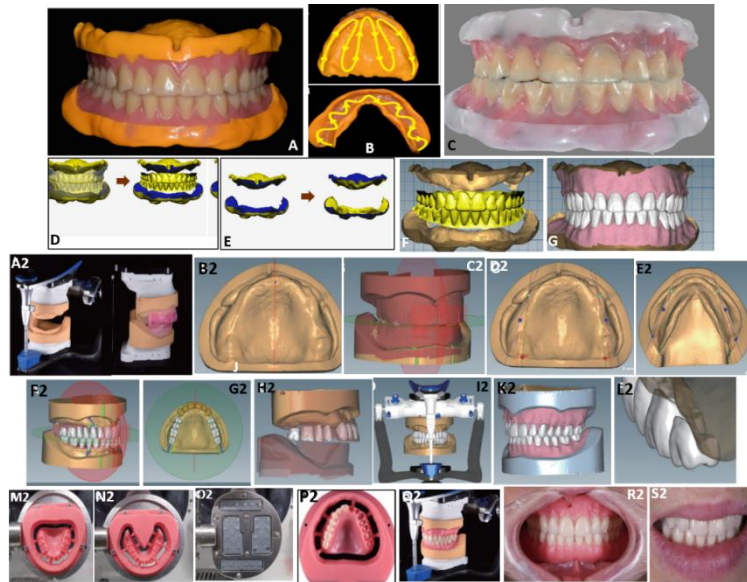

Fig. 5. Using existing denture as close-fitting tray to take functional impression of edentulous arche (A), Optical scanning pathway of impression surfaces of dentures (B), Whole digitized denture image aligned to the centric relation position by using a digital bite scan (C), Formation of maxillary and mandibular digital working models for denture design, Segmentation of whole scan image into the maxillary and mandibular impression part, and dentition part (D-E), Conversion of the negative form of the digitized impression image into positive form using image reversal technique to generate digital working models (D-E), Design of definitive denture on the digital working mode, Import of the dentition part image of the existing denture as a reference in the inter-arch space (F), Design of definitive denture (G). Mounted master casts, master casts and record bases fixed on articulator (Fig. 5A2), Reference points marked on master casts in CAD software [Midline maxillary tuberosity (Fig. 5B2), Occlusal plane (Fig. 5C2), Final setup lines for maxilla (Fig. 5D2), and for mandible (Figure 5E2), Artificial teeth arrangement (Figure 5F2), in Maxilla (Fig. 5G2), and arrangement in scanned record rim (Fig. 5H2), Articulator mounting (Fig. 5I2), Denture design (Fig. 5K2), Basal adaptation of artificial teeth (Fig. 5L2), Milled maxillary (Fig. 5M2), and mandibular wax denture base (Fig. 5N2), Milled artificial teeth (Fig. 5O2), Maxillary upper surface with milled artificial teeth inserted (Fig. 5P2), Milled wax dentures in articulator, notice the contact of incisal pin (Fig. 5Q2), Milled wax denture try-in (Fig. 5R2), and Definitive complete denture inside patient mouth (Fig. 5S2) (lee et al., 2019; Mai et al., 2020).

4. DENTCA Digital Denture/Whole You Nexteeth

Overview: DENTCA's concept is parallel to that of AvaDent, except that DENTCA uses a proprietary impression tray with a detachable and re-connectable two-piece upper tray and a three-piece lower tray with a built-in intraoral tracer. The tray can register a final impression and an interocclusal record simultaneously. The DENTCA system uses one set of impression trays, whereas the AvaDent system requires one set of trays and one AMD [13-14]. The DENTCA technique was presented to the dental schools, centers, and clinics by Whole You, Inc and DENTCA system, Inc, Mitsui Chemicals Group [25].

Manufacturing procedures: Provided upper and lower two-piece trays are selected. These are used to make the definitive impressions and record the two-arches relationship. A #15 surgical blade is used to slice through the impression material on both arches impressions. The anterior sections of the trays are relocated in the mouth for jaw relation records [14,25].

During the first patient visit, anatomical alginate impressions are generated using conventional impression or centric trays (Fig. 5a and b). In addition, the VD and provisional archs relation are registered using the so-called centric tray, and the occlusal plane is determined provisionally using a UTS CAD transfer arch (Fig. 5c). In the laboratory, milled upper and lower

customized trays are arranged (Fig. 5d and e). The UTS CAD device is used to produce key digital model positioned on a virtual articulator (Fig. 5f) [14].

During the second visit, optionally, functional upper and lower silicone impressions are taken (Fig. 5f and g) with milled individual impression trays that already contain the information about the vertical jaw relation and the occlusal plane. If necessary, both impressions can be adjusted by observing the compensation values registered by the UTS CAD transfer arch. The gothic arch is then registered using the functional impressions. A click-in set called gnathometer CAD, which is a cutback, is integrated to leave sufficient space for the intra-oral center-point recording system (Fig. 5h and i). In the laboratory, the gnathometer CAD can be easily clipped to tray impressions and does not require retention (Fig. 5K and l). Gysi Gothic arch paths meet at an equilibrium

area used as a reference during the inter-arch relationship recording step. Then, Gysi Gothic arch is registered with Gnathometer® (Fig. 5m and n). The embedded functional impressions are scanned, and a drawing of the coming CD base is gained. Artificial teeth arrangements are proposed by the 3-shape software with posterior teeth positioned in an ideally bilateral balanced occlusion concept. Then, virtual wax final step was digitally accomplished. Finally, the manufactured upper and lower templates are presented on a white PMMA disc (Fig. 5).

Third appointment. The CECD insertion is almost identical to that of a conventionally made CD. Pressure indicator paste is used. Intra-oral occlusal adjustment might be important and could be performed. Severe disparity in occlusal contacts between the CDs can be corrected after a clinical remount laboratory step. [13,14,25].

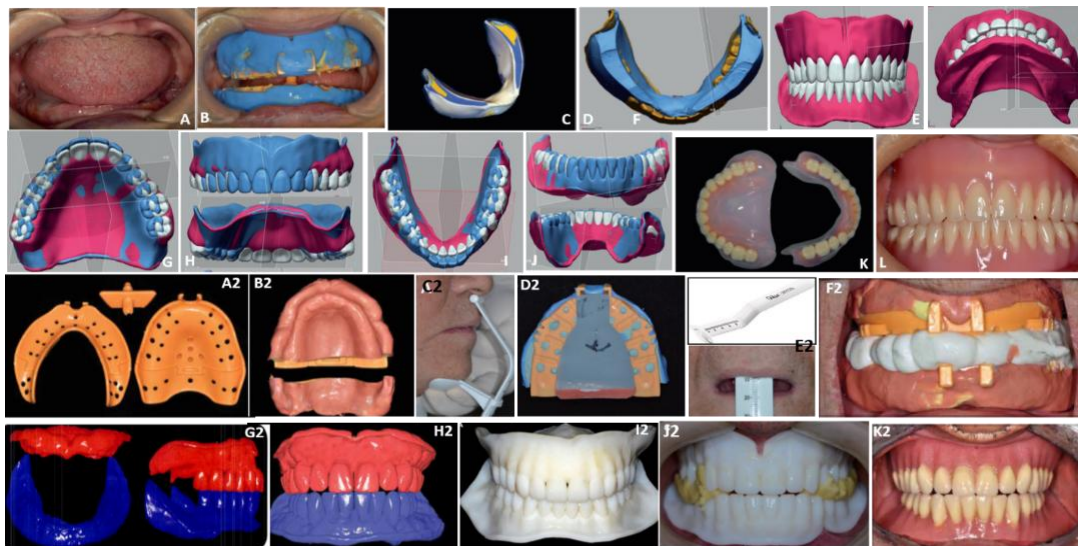


Fig. 6. Maxillary and mandibular arches with severe ridge resorption (A), Definitive impressions and maxillomandibular jaw relationship Registration (B), Impression of mandibular denture cameo surface (piezographic space) made by 3-step procedure in which patient was asked to repeat distinctly pronounced sounds (C), Superimposed piezographic space and original denture design with tooth positions arranged conventionally (D), Comparison between original (left) and modified (right) virtual complete denture images (E and F), Superimposed original and modified virtual complete denture images, Blue area, original design (G-J), Maxillary and mandibular complete dentures milled from acrylic resin block and commercially available denture teeth bonded with resin adhesive (K), Completed dentures inside patient mouth (K) (Ohkubo et al., 2017). Maxillary and mandibular 2-piece impression trays (A2), Posterior part is separated with the use of a blade (B2), Dentca jaw gauge (C2), Dentca Lip ruler (E2), Interocclusal registration material is injected (F2), optical scanning of maxillary and mandibular arch in CR and set-up of anterior teeth (G2), Virtual try-in denture, try-in denture (I2), Jaw relation recording on try-in denture (J2), and Definitive complete denture inside patient mouth (K2) (Steinmass et al., 2017; Contrepolis et al., 2018; Srinivasan et al 2019).

5. Weiland Digital Denture

Overview: The protocol of Wieland Digital Dentures contains four appointments, which are necessary for the fabrication of CECD. Otherwise, three dental appointments are essential if the try-in session is omitted. This technique uses subtractive manufacturing to fabricate CECDs. The clinical records can be gained by duplicating existing CDs and transferring them to the dental laboratory by means of wax rims that are digitally designed and milled or by means of numerically designed and customized impression trays with mutual bite plates [13,14,26].

Fabrication procedures: In the clinic, upper and lower primary impressions are completed with PVS impression material and prefabricated trays. The provided centric record device is manipulated to record the preliminary CR and vertical relationship. The system uses this data to customize impression trays through integrated bite plates. A device similar to a facebow (UTS CAD, Ivoclar Vivadent, Inc) is connected to the handle of the centric tray to help the clinician measure the camper and interpupillary lines. The position of the occlusal plane can be read from the dimensions gained from the camper and interpupillary line scales. The preliminary impressions, centric tray, and the camper and interpupillary line measurements are directed to the laboratory operator.

In the laboratory, the preliminary impressions and the interocclusal record are scanned. Camper line and interpupillary line values are entered into the design software, which then produces virtual models of the edentulous jaws and determines the patient-specific occlusal plane. Customized impression trays with integrated occlusion plates are designed with a uniform offset to allow for the application of impression material and with a recess to allow the stabilization of the Gnathometer CAD (Ivoclar Vivadent, Inc), which is a device that allows the tracing of the gothic arch and records CR.

Intraorally, the customized impression trays are border molded, and then, a definitive impression is made using a PVS material. The UTS CAD is used again to verify the occlusal plane. The Gnathometer CAD is close to the customized trays. The patient's midline, smile line, and canine-to-canine line are established, and the VDO and CR are resolute with traditional systems.

In the laboratory, the records and the functional impressions are scanned, and the occlusal plane is recorded. At this step, the denture teeth are chosen from the software library of denture teeth, and the design program advises a virtual tooth setup. The tooth setup can be modified according to the demands of the clinician and patient or finalized by adding the gingival portion of the dentures if no changes are requested. If the clinician sensations more calm, then ordering a try-in denture to evaluate aesthetics, phonetics, as well as function to allow improvements to the try-in denture if it is necessary, after-that, the dental technician can mill a monolithic PMMA try-in CD. A prepolymerized disk is used to mill the gingival portion of the denture bases. The bases include milled recesses, in which the denture teeth will be bonded with the use of a positioning jig.

Clinically, after the milling of the CD, the placement is performed. Assignment is analogous to that of any conventional CD. Occlusal corrections can be achieved intraorally or by using a clinical remount appointment [13-14,26].

6. VITA VIONIC VIGO (VITA Zahnfabrik)

The VITA VIONIC VIGO technique offers materials for open CECD systems. The digital proposal and construction can be facilitated by non-system-inherent scanners, software, and milling machines. The system supports whatever adjustment protocol to which the user is familiarized. Hence, a five-step conventional CD production procedure can be applied. Otherwise, a reduced-session protocol with only three sessions (anatomical impression, functional impression plus determination of vertical and maxillomandibular jaw relation, and denture placement) can also be useful. The impressions, casts, or registrations are generated conventionally and digitalized, thereby entering the CECD workflow. If a try-in session is chosen, the try-in dentures can be milled from wax discs provided by VITA system [13,27-28]. VITA VIONIC VIGO is the first denture tooth that has been perfected for the digital workflow. The tooth has already been preconditioned and shortened basally. After the additive or subtractive fabrication of the denture bases, it is simply removed from the blister pack and fixed into the designed alveoli using the special VITA VIONIC BOND adhesive. The bond is extremely thin and clean. Moreover, it saves time because of the precise and stable fit. Any person can fit it.

Sometimes, just a small detail is missing to make this technology work for everyday laboratory use.

Fig. 7 shows the procedures for the construction of CECDs [27-28].

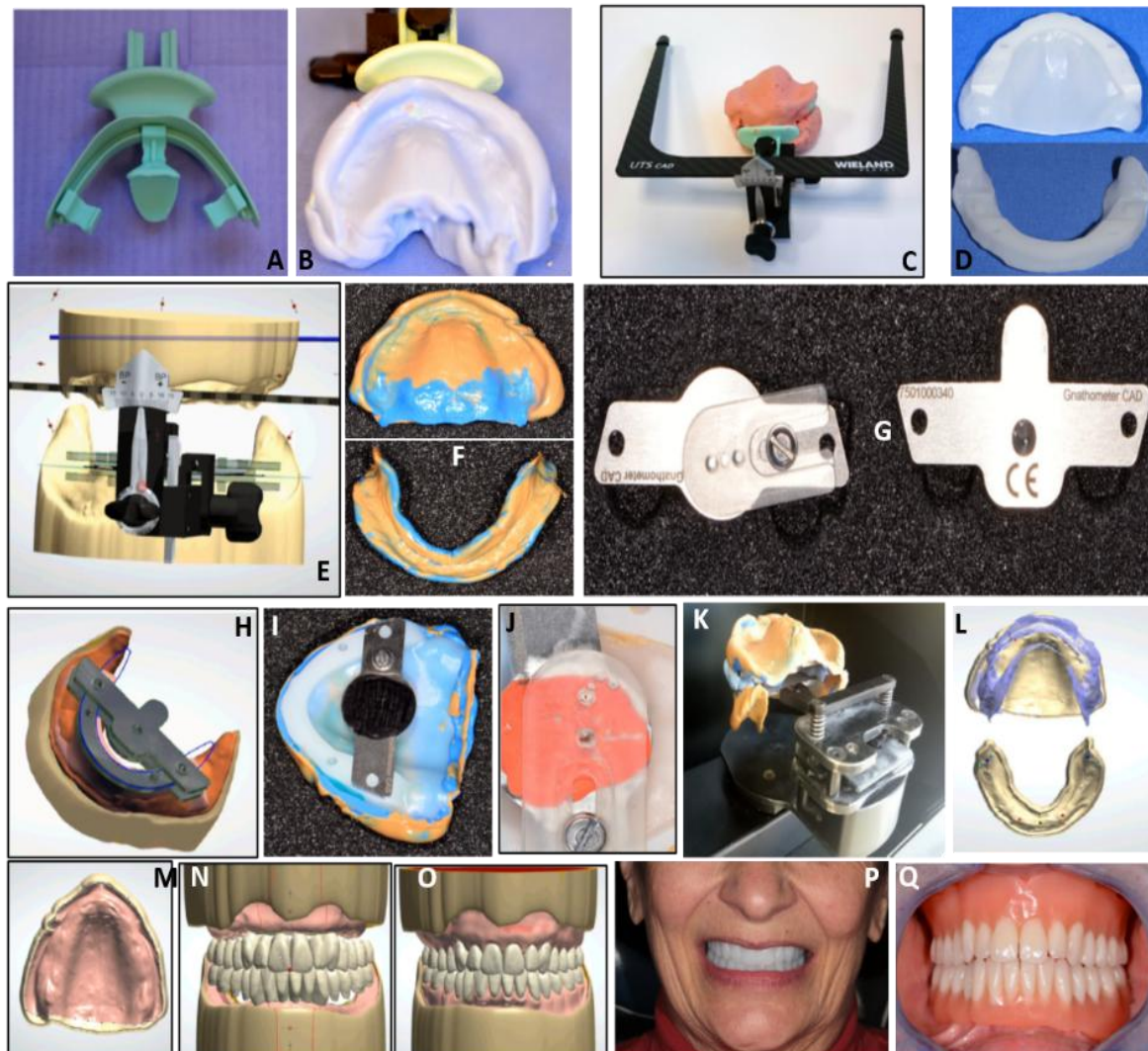


Fig. 7. Centric Tray®, Recording of preliminary inter-arch report with the Centric Tray® and high viscosity elastomer, UTS CAD® (A-B), UTS CAD® device connected to the Centric Tray® for recording deviations from reference planes (C), Maxillary and mandibular individual milled tray (D), Values of UTS CAD® device are used to create primary digital model positioned on virtual articulator (E), Maxillary and Mandibular conventional functional impression with manufactured tray (F), Gnathometer® (G), cutback is integrated to leave sufficient space for intra-oral center-point recording system (Gnathometer®) and to avoid any interference between antagonist occlusal rims (H), Gnathometer® clipped to tray impressions and without bonding or retention (I), Gysi Gothic arch paths meet at an equilibrium area used as a reference during inter-arch relationship recording step (J), Embedded functional impressions are scanned (K), Numerical models are placed on virtual articulator and identified reference points (L), Drawing of limit of future denture base (M), A teeth setting is proposed by 3shape software with posterior teeth positioned in an ideally bilateral balanced occlusion concept (N), Virtual waxes finishing step (O), Occlusion rims are validated and patients use their manufactured template for functional validation (mastication and phonation) for while at home (P), Dentures are tried, and primary equilibration is performed (Q) (Baba, et al., 2016; Bonnet et al., 2017; Steinmass et al., 2017)

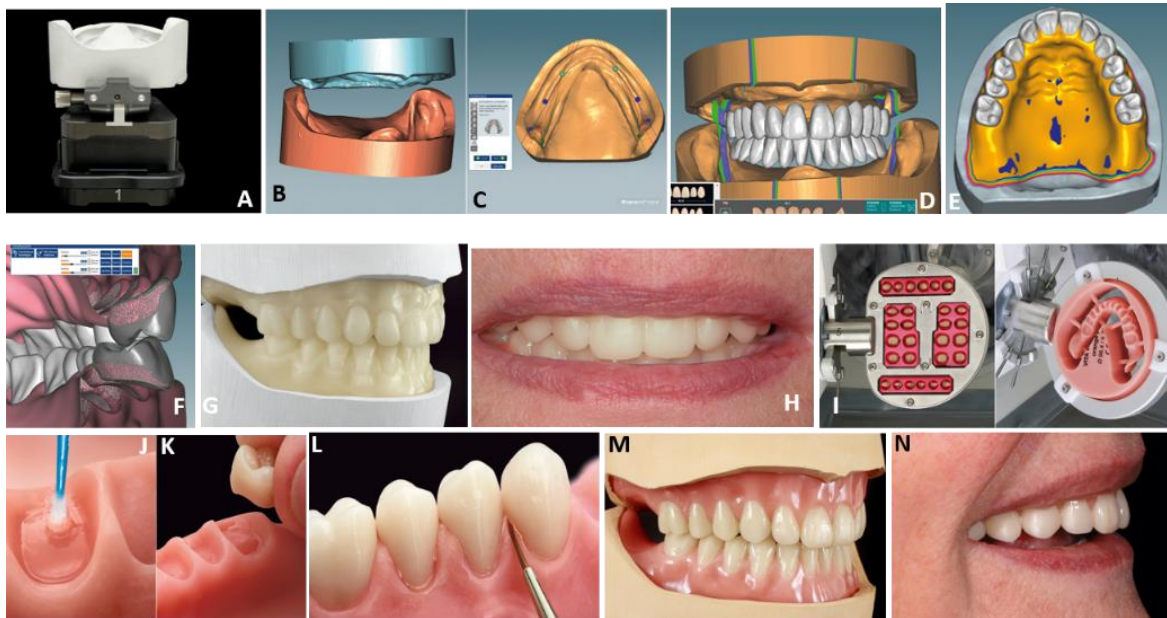


Fig. 8. Mandible model before digitalization with laboratory scanner (A), Digitalized model in clinically determined vertical dimension (B), Model analysis by Software (C), Virtual setup was performed by pushing button after tooth selection (D), Design of denture base (E), Cross-sectional view of ideal dentition in molar area (F), CAD/CAM-fabricated wax try-in was made Midline(G), occlusion level and phonetics were checked using a wax try-in (H), Modification of teeth, teeth in the VITA VIONIC FRAME were modified circularly and basally (I), Denture base was fabricated from PMMA blank VITA VIONIC BASE (J), Milled PMMA alveoli were moistened with VITA VIONIC BOND, dislodged basal teeth bonded with adhesive, accurately fitting in denture (K), Closing of interdental spaces with veneering composite VITA VM LC flow (L), After polymerization in the pressure pot and final polishing is done (M), Denture in the patient mouth (N). Patient was enthusiastic about the positional stability and natural effect of the VITAPAN EXCELL denture teeth [Körholz K-H, 27-28]

3. DISCUSSION

Currently, the six available CECD fabrication systems offer a number of advantages, and the decision on which technique to use may be contingent on the dentist's prosthodontic expertise, patient output amount, and requirements concerning denture individualization. Nowadays, the progress in the use of CECDs to produce RP or complete dentures has been exponential in dental centers, private clinics and specialized hospitals, and the number of commercially existing CAD/CAM denture systems increases yearly [14,29]. Fig. 9 gives a summary of the steps of the 6 available systems.

Mai and Lee., 2020 described a well-organized digital workflow for recording functional edentulous arch images with precise inter-arch relationship (centric relation). In addition, exact

tooth setup in CAD programs is established by using intraoral scanner for an existing denture and digital denture scanning. The new denture can be planned competently and predictably [24]. Goodacre et al., 2018 described a technique by using intraoral scanning to capture CD impressions. This scanner can capture an accurate mucostatic impression and results in a good mucosal adaptation and stability of the CECD milled prostheses. This system can record the CR and is efficient in the clinical steps. It minimizes the need to transport conventional records to the dental technicians [20].

Steinmassl et al., 2017 stated that the existing CAD/CAM denture fabrication systems offer a variation of advantages, and the choice on which technique to use should rely on the prosthodontic and dental technicians' expertise, patient amount rate, and necessities concerning denture individualization [13].

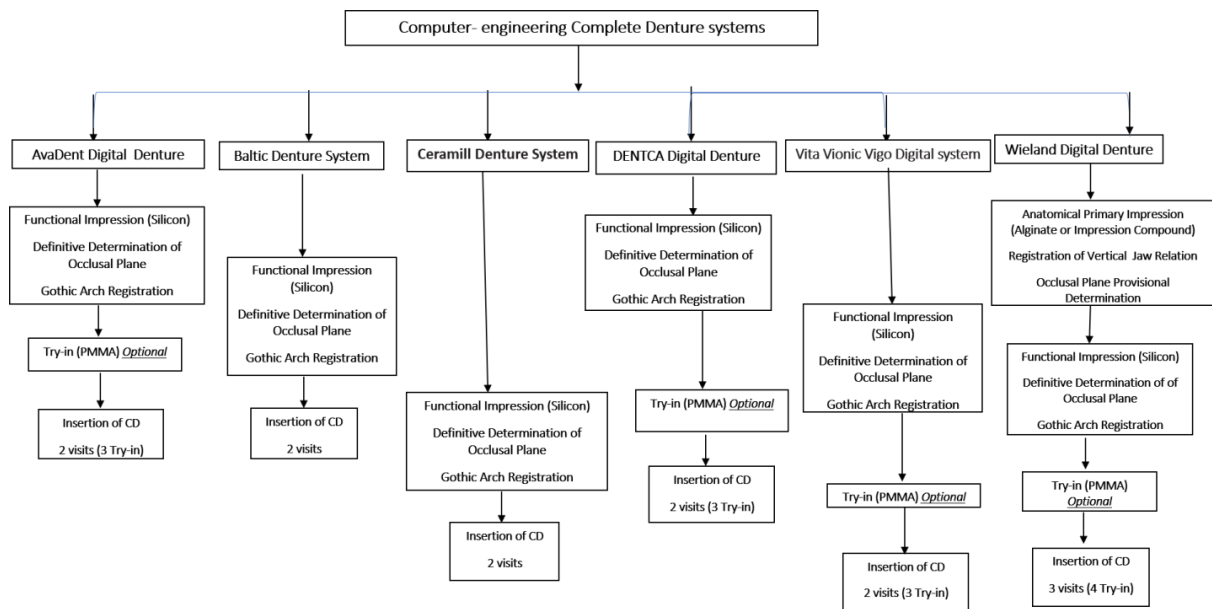


Fig. 9. Summary of the steps of the different CECDs construction systems

Srinivasan et al., 2019 published a technical statement describing the workflows for manufacturing CECDs by using a novel, custom-modified tray to successfully fabricate CAD-CAM milled CDs and resin interim removable partial denture [21]. Also, AlHelal et al., 2017 and Batisse et al., 2021 tried to overcome the difficulties regarding digital performances that can result in additional appointments and costly remakes of CEM-CDs. They presented a good technique that resulted in good aesthetics, fitting, and retention [4, 30].

Pacquet et al., 2021 said that composite resin and lithium disilicate glass-ceramic material reveal acceptable dimensional accuracy, and milling glass-ceramic before crystallization significantly enhances dimensional accuracy [31].

Every system has a drawback. For example, in AvaDent, the adjustment steps are made in one session, which may be stressful for CAD/CAM-denture learners. However, the system was graded as “easier to perform” than the other systems. Failure can be adjusted during the try-in step [13-14]. In addition, this system is the most used for fabricating different type of prostheses and can accommodate many steps and instruments or materials from other types of procedures (Figs. 1–3). BDS cannot fabricate a single-arch denture; dysgnathia also represents a limitation; and training is needed before it can be applied to patients [13-14,22]. Some digital systems do not offer a try-in step, which can

cause complications during delivery. DENTCA DD can be used in the presence of severe bone ridge resorption.

The system used does not offered all schemes of upper and lower teeth relationship during function and is only available with a lingualized occlusion opportunity. No long-term clinical research outcomes and good results have been published. Current commercial protocols should be validated through sound clinical case control and long-term laboratory investigations and improved if required to overcome the numerous disadvantages listed. Clinician feedback is critical if the manufacturers wish to progress the current treatment protocols.

Six systems exist, and others are being developed. Clinical and laboratory investigations have been conducted, but not on all of the available systems. Nevertheless, current research indicates that this talented digital workflow benefits both the dental technician and the dentists or clinicians.

4. CONCLUDING REMARKS

Based on the findings of this systematic review of CECDs, the following conclusions are drawn:

- Techniques and machines are continually changing and improving in mechanical and surface properties to overcome and/or minimize the patient’s overall dissatisfaction in terms of aesthetic, bulkiness, and inadequate retention.

- In all techniques, post insertion adjustments are performed in the conventional way. The systems can accept the using of old dentures if they are utilized in the try-in for the new CECD fabrication. Most of the systems accept external staining for denture teeth.
- Try-in for the virtual dentures is highly recommended in all techniques, because it minimizes most of the negative outcomes in various aspects, such as aesthetics, retention, size of selected teeth, vertical dimension of occlusions, centric relation verification, and overall profile of the patient face. In most of the techniques, the white acrylic resin is used.
- Issues in the interpretation of the digital preview was recognized as a unique difficulty related to the fabrication of CECDs.
- Each technique has its own advantages, disadvantages, and limitations, but all techniques preserve a digital record, which is a great advantage for older adults with limited access to dental care.
- Other advantages of CECD fabrication techniques over conventional ones are as follows: elimination of the use of stone, flasking, and processing techniques; and absence of monomer usage and its effects.

CONSENT

It is not applicable.

ETHICAL APPROVAL

It is not applicable.

COMPETING INTERESTS

Authors have declared that no competing interests exist.

REFERENCES

1. AlHelal A, AlRumaih H, Kattadiyil MT, Baba NZ, Goodacre CJ. Comparison of retention between maxillary milled and conventional denture bases: A clinical study. *J Prosthet Dent.* 2017;117:233-8.
2. Baba NZ, AlRumaih HS, Goodacre BJ, Goodacre CJ. Current techniques in CAD/CAM denture fabrication. *General dentistry.* 2016;64(6):23-28.
3. Batisse C, Nicolas E. Comparison of CAD/CAM and Conventional Denture Base Resins: A Systematic Review. *Appl Sci;* 2021;11:5990. Available:<https://doi.org/10.3390/app11135990>.
4. Bidra AS, Taylor TD, Agar JR. Computer-aided technology for fabricating complete dentures: Systematic review of historical background, current status, and future perspectives. *J Prosthet Dent.* 2013;109:361–366.
5. Bonnet G, Batisse C, Bessadet M, Nicolas E, Veyrune JL. A new digital denture procedure: A first practitioners appraisal. *BMC Oral Health.* 2017;17:155.
6. Contrepois M, Sireix C, Soenen A, Pia JP, Lasserre JF. Complete denture fabrication with CAD/CAM technology: A case report. *Int J Esthet Dent.* 2018;13(1):66-85.
7. Fang Y, Fang JH, Jeong SM, et al. A technique for digital impression and bite registration for a single edentulous arch. *J Prosthodont.* 2019;28:e519-5235.
8. Gimenez-Gonzalez B, Hassan B, Ozcan M, et al. An *in vitro* study of factors influencing the performance of digital intraoral impressions operating on active wavefront sampling technology with multiple implants in the edentulous maxilla. *J Prosthodont.* 2017;26:650-655.
9. Goodacre BJ, Goodacre CJ, Baba NZ, Kattadiyil MT. Comparison of denture tooth movement between CAD-CAM and conventional fabrication. *J of Prosthodont.* 2018;119(1):108-115.
10. Goodacre BJ, Goodacre CJ, Baba NZ, Kattadiyil MT. Comparison of complete denture base adaptation between CAD-CAM and conventional fabrication techniques. *J Prosthet Dent.* 2016;116:249-56.
11. Goodacre CJ, Garbacea A, Naylor WP, Daher T, Marchack CB, Lowry J. CAD/CAM fabricated complete dentures: Concepts and clinical methods of obtaining required morphological data. *J Prosthet Dent.* 2012;107:34–46.
12. Han W, Li Y, Zhang Y, Lv Y, Zhang Y, et al. Design and fabrication of complete dentures using CAD/CAM technology. *Medicine.* 2017;96:1-8.
13. Available:<https://www.vita-zahnfabrik.com/en/VITA-VIONIC-VIGO-92199,27568.html>.

14. Infante L, Yilmaz B, McGlumphy E, Finger I. Fabricating complete dentures with CAD/CAM technology. *J Prosthet Dent.* 2014;111:351–355.
15. Inokoshi M, Kanazawa M, Minakuchi S. Evaluation of a complete denture trial method applying rapid prototyping. *Dent Mater J.* 2012;31:40–46.
16. Kanazawa M, Inokoshi M, Minakuchi S, Ohbayashi N. Trial of a CAD/CAM system for fabricating complete dentures. *Dent Mater J.* 2011;30:93–96.
17. Kattadiyil MT, AlHelal A. An update on computer-engineered complete dentures: Literature review on clinical outcomes. *J Prosthet Dent.* 2017;117:478–85.
18. Kattadiyil MT, Goodacre CJ, Baba NZ. CAD-CAM complete dentures: A review of two commercial fabrication systems. *J Calif Dent Assoc.* 2013;41:407-16.
19. Kawahata N, Ono H, Nishi Y, Hamano T, Nagaoka E. Trial of duplication procedure for complete dentures by CAD/CAM. *J Oral Rehabil.* 2017;24:540–548.
20. Körholz KH. VITA VIONIC SOLUTIONS: Denture fabrication at the touch of a button; 2017. Available:<https://www1.dental-visionist.com/en/VITA-VIONIC-SOLUTIONS-Denture-fabrication-at-the-touch-of-a-button-772.html?kategorie=1879>
21. Lee Y, Kwon K-R, Pae A, Noh K, Paek J, Hong S-J. Rehabilitation of fully edentulous patient using Ceramill full denture system (FDS). *J Korean Acad Prosthodont.* 2019; 57:232-7.
22. Maeda Y, Minoura M, Tsutsumi S, Okada M, Nokubi T. A CAD-CAM system for removable denture. Part I: Fabrication of complete dentures. *Int J Prosthodont.* 1994;7:17-21.
23. Mai H, Lee D. A digital technique to replicate edentulous arches with functional borders and accurate maxillomandibular relationship for digital complete denture. *Journal of Prosthodontics.* 2020;29:356–359.
24. Masri G, Mortada R, Ounsi H, et al. Adaptation of complete denture base fabricated by conventional, milling, and 3-d printing techniques: An in vitro study. *J Contemp Dent Pract.* 2020;21(4):367–371.
25. Ohkubo C, Shimpo H, Tokue A, Park E, Kim TH. Complete denture fabrication using piezography and CAD-CAM: A clinical report. *The Journal of Prosthetic Dentistry.* 2018;119(3):334-338.
26. Pacquet W, Tapie L, Mawussi B, Boitelle P. Volumetric and dimensional accuracy assessment of CAD/CAM-manufactured dental prostheses from different materials. *J Prosthet Dent.* 2012;54.
27. Raszewski Z. Acrylic resins in the CAD/CAM technology: A systematic literature review. *Dent Med Probl.* 2020; 57(4):449–454. DOI:10.17219/dmp/124697.
28. Srinivasan M, Kamnoedboon M, McKenna Lea G, Martin A, Mutlu S, Müller OF. CAD-CAM removable complete dentures: A systematic review and meta-analysis of trueness of fit, biocompatibility, mechanical properties, surface characteristics, color stability, time-cost analysis, clinical and patient-reported outcomes. *J Dentistry.* 2021;113:103777.
29. Steinmassl PA, Klaunza F, Steinmassl O, Dumfahrt H, Grunert I. Evaluation of currently available CAD/CAM dentures system. *Int J Prosthodont.* 2017;30:116-122.
30. Steinmassl PA, Steinmassl O, Kraus G, Dumfahrt H, Grunert I. Is cognitive status related to oral hygiene level and appropriate for determining need for oral hygiene assistance? *J Periodontol.* 2016; 87:41–47.
31. Yilmaz B, Azak AN, Alp G, Eks H. Use of CAD-CAM technology for the fabrication of complete dentures: An alternative technique. *J Prosthet Dent.* 2017;118(2): 140-43.

© 2021 Moaleem et al.; This is an Open Access article distributed under the terms of the Creative Commons Attribution License (<http://creativecommons.org/licenses/by/4.0>), which permits unrestricted use, distribution, and reproduction in any medium, provided the original work is properly cited.

Peer-review history:
The peer review history for this paper can be accessed here:
<https://www.sdiarticle5.com/review-history/78337>