



Clinico-pathological and Immunohistochemistry of Newcastle Disease in Indigenous Chickens and Some Wild Birds in Plateau State, Nigeria

**Kumbish, Peterside Rinle¹, Oladele, Sunday Blessing²,
Esievo, King Akpofure Nelson², Ibrahim, Najume Doguwa Giginya²,
Ahmed, James Saidu¹, Moses, Gyang Davou¹, Rimfa, Amos Gambo¹,
Choji, Tobias Pwajok Peter¹, Ugbe, Aondona Dominic¹,
Anueyiagu, Deborah Mojisola¹, Atam, Sunday Kelvin¹, Shekaro Audu¹
and Barde, Israel Joshua^{1*}**

¹Central Diagnostic Laboratories, National Veterinary Research Institute, Vom, Nigeria.

²Department of Veterinary Pathology, Ahmadu Bello University, Zaria, Kaduna State, Nigeria.

Authors' contributions

This work was carried out in collaboration among all authors. Authors KPR, OSB, EKAN and INDG designed the study and wrote the protocol and interpreted the data. Authors AJG, MGD, RAG, CTPP and UAD anchored the field study and gathered the initial data. Authors ADM, ASK, SA and BIJ performed preliminary data analysis, managed the literature searches and produced the initial draft. All authors read and approved the manuscript.

Article Information

DOI: 10.9734/JAMB/2019/16i430129

Editor(s):

(1) Dr. Niranjala Perera, Department of Food Science and Technology, Wayamba University of Sri Lanka, Sri Lanka.

(2) Dr. P. Rama Bhat, PG Biotechnology, Alva's College, Karnataka, India.

Reviewers:

(1) Mostafa Abbas Mostafa Shalaby, Cairo University, Egypt.

(2) Lew Kan Sprenger, Centro Universitário Vale do Iguaçu, Brazil.

Complete Peer review History: <http://www.sdiarticle3.com/review-history/49616>

Original Research Article

**Received 03 April 2019
Accepted 19 June 2019
Published 24 June 2019**

ABSTRACT

Aim: Newcastle disease (ND) is one of the most important avian diseases. Virulent strains of Newcastle disease virus (NDV) have the potential of rapid spread, and may cause serious economic impact and international trade restrictions for the poultry industry. The objective was to study the clinical, gross and histo-pathological and immunohistopathological changes of Newcastle disease infection in apparently healthy and sick indigenous chickens, ducks, pigeons and some

*Corresponding author: E-mail: israelbarde@yahoo.com;

wild birds in Plateau State.

Methodology: The indigenous chickens used in this study were randomly selected from apparently healthy and from those with suggestive clinical signs of ND. A total of 638 birds were used for the study. Out of the total number of birds sampled, 349 were indigenous chickens, 98 pigeons, 96 ducks and 95 from different species of wild birds. Out of the number sampled from indigenous chickens, 169 (44.01%) were live birds, while 180 (46.90%) were carcasses. Tissues were collected from indigenous chickens, pigeons, ducks and some wild birds from both sick, and apparently healthy unvaccinated flocks to screen for the presence of NDV by immunohistochemical (IHC) techniques. The histopathology and immunohistochemistry were done using standard laboratory procedures.

Results: Clinical signs observed in live birds generally varied from weakness, greenish watery diarrhoea, respiratory difficulty, anorexia and coughing, torticollis, droopy wings, paralysis, partial leg paralysis, and opisthotonos. Generally, the gross lesions in euthanized and dead birds were mostly hyperaemia, hepatomegaly, splenomegaly, moderate enlargement of the heart, petechial haemorrhages on the mucosa surface of the proventriculus and haemorrhagic tracheitis, congestion and moderate enlargement of the pancreas, pulmonary congestion and congested kidneys. Histopathological changes include lymphoid depletion and connective tissue proliferation, enteritis, pulmonary congestion and splenitis. A total of six samples (1.56%) out of 349 from indigenous chickens had positive staining for NDV antigen using IHC technique. While there were only two samples out of the 95 wild birds samples positive by IHC, both of the positive samples were from Red-eyed Dove (*Streptopelia semitorquata*), resulting in a 25% (2/8) positive rate from this species; had positive staining for NDV by immunohistochemistry. All IHC positive cases in this study, in both wild birds and indigenous chickens shared similar staining patterns.

Conclusion: The study also shows that NDV antigens in wild birds and indigenous chickens concentrate more in the spleen, pancreas, trachea and proventriculus. This study, presents for the first time to the best of our knowledge that viral antigens (NDV) in wild birds and indigenous chickens were demonstrated by immunohistochemical technique in Plateau State, Nigeria.

Keywords: Clinico-pathological; indigenous chickens; immunohistochemical; Nigeria; newcastle disease virus; wild birds.

1. INTRODUCTION

Newcastle disease is one of the most important causes of mortality in indigenous chickens and many species of domesticated and wild birds have been found susceptible to this disease. A flock of chicken that are kept under free-range management and on which no selection of breeds or improvement by crossbreeding has been done is considered as a flock of indigenous chicken [1]. Indigenous chicken lay between 8 and 15 eggs per clutch, depending on availability of feed [2]. They are broody and hatch about 80% of the eggs they sit on. They attain 2-3 clutches in a year [3].

The few 20-30% chicks that attain maturity form most of the replacement stock of these birds, though under poor management, they still can live within the family for many years [4]. They form an important part of family life, playing important cultural roles besides being a valuable source of protein and income. Indigenous chickens have not attained their full production potential due to exposure to risks that militate

against their survival and productivity. Constraints to production include diseases, predators and poor nutrition [5]. Indigenous chicken can be profitable, if managed well. Control of common diseases in the free-range system could improve survival rate of chicks by at least 30%, while improved feeding, housing and disease control could increase survival rate to 80%. Additional losses to the poultry industry arise from the restriction on exportation of live and dressed fowl across the globe [6].

Newcastle disease (ND) - a List A infection considered as one of the two most important diseases of chickens along with highly pathogenic avian influenza [7] is an economically important disease causing heavy production loss to the farmers besides high mortality worldwide. The disease affects 27 of the 50 orders of birds [7]. The disease is caused by Avian Paramyxovirus type 1 (APMV 1) of the genus *Avula virus* under the family *Paramyxoviridae*. The virus has a negative sense, single stranded - RNA genome that consist of approximately 15 kbp (15,186 bp). The genome contains six major genes that

encode the structural proteins in the order 3'-NP-P-M-F-HN-L-5. In Nigeria, ND is endemic [7]. The first documented outbreak of the disease occurred in Ibadan in 1952 [8]. Since then, ND has been the most important disease of chickens in Nigeria [9]; apart from highly pathogenic avian influenza (HPAI) in the recent past. Newcastle disease continues to be a serious economic threat to the poultry industry due to increased morbidity and mortality rates and loss of eggs for both breeding and human consumption. Newcastle disease was reported in exotic and local chickens [5,10-14].

The introduction of NDV in a village, most likely occurs when infected live chickens are introduced. Live bird markets are probably a major means of spread [6,15], particularly since many village poultry owners take birds to markets as soon as they become sick, in an attempt to get some economic benefit [15]. Other means of introducing new strains of ND to a village poultry population include wild birds, live infected chickens being transported through the village, infected carcasses, and movement of objects from infected site [16]. The aim was to study the clinical, gross and histo-pathological and immunohistochemical changes of Newcastle disease infection in apparently healthy and sick indigenous chickens, ducks, pigeons and some wild birds in Plateau State. To the best of our knowledge there is paucity of information on the histo-pathological and immunohistopathological changes of Newcastle disease in indigenous chickens in the study area.

2. MATERIALS AND METHODS

2.1 Study Area

This study was carried out in Plateau State of Nigeria. The State is located in the central geographical zone of the country (between Lat. 8° and 10° North and Log. 7° and 11° East), bounded by Bauchi State to the East, Taraba State to the south east, Nasarawa State to the South and Kaduna State to the North. It has an average ambient temperature of 24°C and relative humidity of 50%. The State has an approximate human population of 3.5 million with over 30 ethnic groups [17,18]. The study was from February 2012 to March 2013.

Plateau State has an estimated commercial poultry population of 808,298. The highest concentration of this figure are found in the two Local Government Areas (LGAs) of Jos North

and South, accounting for 620, 540, while the remaining 15 LGAs account for 187, 758 [19].

Plateau State has an altitude ranging from 1, 200 metres to a peak of 1, 829 metres above sea level in Shere hills. The State has a land area of 30, 913 km². Its mean annual rainfall varies between 1, 317 mm in the Southern part of the State and 1460 mm on the high Plateau [20].

2.2 Sampling of Birds

The different species of birds used for this study were sampled with a purposive sampling method that included birds used for this study that had signs consistent with NDV infection from three geographical zones i.e. Southern, Central and Northern Zones of Plateau State. Equal number of chickens was sampled per zone. The wild birds were identified by an ornithologist at the University of Jos, Plateau State, Nigeria.

2.2.1 Category of birds sampled

(1) Carcasses or live birds captured for gaming purposes, (2) Birds shot during hunting, (3) Diseased or hunted birds, (4) Apparently healthy, sick or moribund indigenous poultry in selected areas of study and (5) Wild birds or local chickens found dead or are dying and submitted to the Central Diagnostic Laboratory, National Veterinary Research Institute, Vom, Plateau State, Nigeria. Samples of liver, kidney, spleen, lung, intestine and brain were collected from a total of 349 indigenous chicken, 98 pigeons, 96 ducks and 95 wild birds.

2.2.2 Clinical and pathological examinations

Clinical signs of ND where applicable, in live birds were examined and noted, when applicable. Post-mortem examinations of the different bird species that died of ND were conducted. Gross lesions observed in the spleen, liver, kidneys, lungs, intestine, proventriculus, trachea, and brain from apparently healthy and sick village chickens, ducks and pigeons, wild and captive birds in different locations in Plateau State, Nigeria during the study were recorded.

2.2.3 Histopathological examination

Samples of liver, kidney, spleen, brain, intestine, testis, tracheas, proventriculus, conjunctival sacs and lungs were fixed in 10% buffered formalin. All fixed tissue samples were embedded in paraffin wax, and sectioned at 3 µm and then

routinely deparaffinised and stained with H & E for histopathological examinations [21]. Processed slides were examined under light microscope and photomicrograph of the lesions were snapped with digital camera and documented accordingly.

2.2.4 Immunohistochemical examination

Tissue blocks of lungs liver heart, spleen, trachea, brain, proventriculus, intestine, conjunctiva sac and pancreas were prepared histologically at the National Veterinary Research Institute, Vom, Plateau State, Nigeria. The samples were packaged and transported to the Department of Veterinary Pathology University of Georgia, Atlanta (UGA), Athens, USA, for immunohistochemical studies.

2.2.5 Immunohistochemistry protocol

Deparaffinized and hydrated sections of the tissues were soaked in 0.3% H₂O₂ (v/v) in 100% methanol for 30 minutes at room temperature. The sections were subjected to antigen retrieval by microwaving for 10minutes at full power in 0.1 M citrate buffer, followed by blocking with 1% bovine serum albumin (BSA) in PBS (pH 7.4). Slides were then incubated in primary antibody (a mouse-derived monoclonal antibody against NDV F protein which was produced by Hu et al. [22]). The antibody was diluted 1:8000 in PBST (PBS with 0.05% Tween20), containing 0.1% BSA for 2 hours at 37°C. After washing, sections were incubated with secondary antibody (peroxidase conjugated goat-anti-mouse IgG (Sigma, St Louis, MO, U.S.) diluted 1:250 at 37°C for 1hour. Substrate development was with 3, 3'-diaminobenzidine (DAB) (Boster, Wuhan, China). Sections were counterstained lightly with hematoxylin. For each tissue specimen in this study, a duplicate set of tissue sections were also prepared using the same steps, but omitting the incubation with the primary antibody for control. A semi-quantitative scoring of IHC staining was conducted as described by Saidu et al. and Brown et al. [23,24].

2.3 Data Analysis

The data obtained from this study were analysed using simple descriptive analysis.

3. RESULTS

Tables 1 and 2 show the total number of species of birds from which samples were taken for histopathology and immunohistochemical studies:

Clinical Manifestations of ND

The number and species of birds in this study that were alive and showed clinical signs suggestive of ND are shown on Table 3. The affected live indigenous chickens showed clinical signs of weakness, listlessness, greenish watery diarrhoea, matted vents (Plates I-III). The obvious signs in the wild birds that were caught alive were weakness, inability to fly and shivering associated with ruffled feathers as demonstrated in carcass (Plate IV). The pigeons showed in-appetence, listlessness and greenish white diarrhoea (Plate V). Mortality was 100% in the 12 clinically sick indigenous chickens.

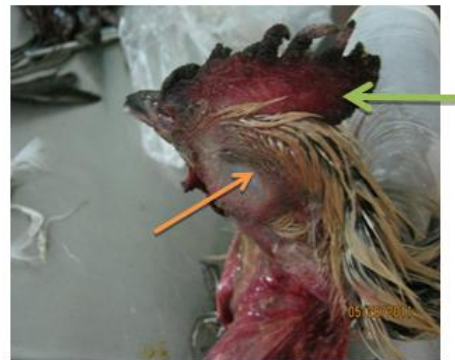

Plate I: Indigenous chicken (*Gallus gallus domesticus*) Note the cyanotic comb and wattles (green arrow), as well as the swollen left eye (yellow arrow)

Table 1. Location, type and number of birds sampled with their percentages (in parentheses)

Location	Type, number of birds and their percentages		
	Indigenous chicken	Ducks	Pigeons
Plateau State, Nigeria			
Northern zone	120 (34.38%)	20 (20.83%)	56 (57.14%)
Central zone	117 (33.53%)	25 (26.04%)	20 (20.41%)
Southern zone	112 (32.09%)	51 (53.13%)	22 (22.45%)
Total	349 (100%)	96 (100%)	98(100%)

Table 2. Number and species of wild birds sampled per zone in Plateau State

S/No.	Species of wild birds	Number of birds per zone		
		NZ	CZ	SZ
1.	Speckled pigeon (<i>Columba guinea</i>)	5	4	3
2.	Laughing dove (<i>Streptopelia senegalensis</i>)	1	3	-
3.	Red-eyed Dove (<i>Streptopelia semitorquata</i>)	4	3	1
4.	Crown Bulbul (<i>Pycnonotus barbatus inornatus</i>)	2	-	-
5.	Grey Plantain eater (<i>Crinifer piscator</i>)	1	-	-
6.	Hooded Vulture (<i>Necrosyrtes monachus</i>)	4	1	1
7.	Variable sun bird (<i>Cinnyris venustus</i>)	2	-	-
8.	Red-Billed Firefinch (<i>Lagonosticta senegala</i>)	4	-	3
9.	Double-spurred Francolin (<i>Francolinus bicalcaratus</i>)	5	3	-
10.	Vinaceous Dove (<i>Streptopelia vinacea</i>)	1	3	1
11.	Bronze mananikin (<i>Sperestes cucullata</i>)	5	3	4
12.	Red-billed Queler (<i>Quelea quelea</i>)	6	2	4
13.	Black kite (<i>Milvus migrans</i>)	4	-	2
14.	Barn owl (<i>Tyto alba</i>)	-	1	2
15.	Weavers (<i>Ploceus luteolus</i>)	-	3	2
16.	Cattle Egret (<i>Bulbulcus ibis</i>)	-	-	2
Total		44	26	25

Key: NZ: northern zone; CZ: central zone; SZ: southern zone

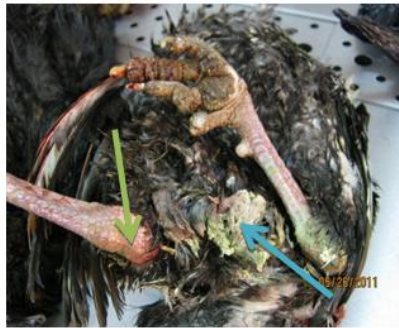

Plate II: Indigenous chicken (*Gallus gallus*). Note the greenish watery faeces staining the vent (blue arrow); and the hyperaemic shanks (green arrow)



Plate IV: The carcass of a red-eyed dove (*Streptopelia semitorquata*) Note the moribund position

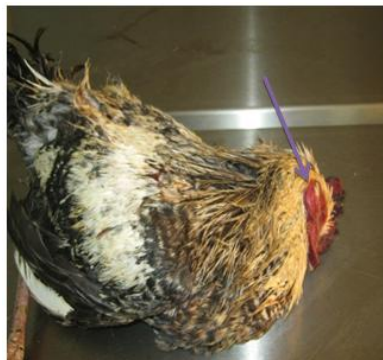

Plate III: The carcass of indigenous chicken Note the twisted neck/ torticollis (blue arrow)



Plate V: Carcasses of Cameroon olive pigeons (*Columba sjostedti*). Note the greenish watery faeces that stained their vents

Gross Pathological Changes Associated with ND

The gross lesions in various organs of all the birds sampled were more in the lungs, trachea as well as the proventriculus. The striking lesions were haemorrhages on the proventriculus, necrosis of the caecal tonsils and of the lymphoid patches along the intestine (Plates VI - X). Lungs had congestion, haemorrhages and oedema, the tracheas showed haemorrhages and hyperaemia mostly (Plates VIII and XIV). The liver showed congestion, and multifocal areas of necrosis. The brain had meningeal capillary congestion, particularly in indigenous chickens and the kidneys showed necrotic spots and haemorrhages. Spleens in some cases were moderately enlarged. Heart lesions were mainly pinpoint haemorrhages of the myocardium. A few pinpoint haemorrhages were present in proventriculus of quite a number of birds. Other gross lesions such as haemorrhages, congestion and focal necrosis were detectable in the conjunctival sac, pancreas, testes and intestines.

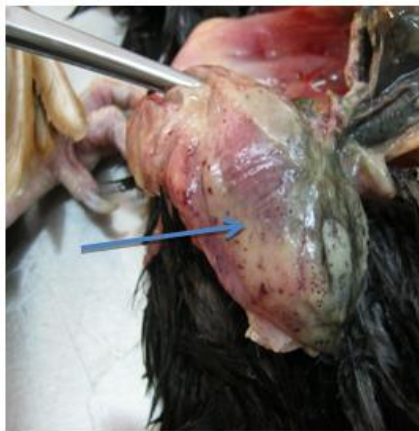

Plate VI: Gross pathological change on the subcutaneous fat of indigenous chicken (*Gallus gallus*). Note the petechial haemorrhages on subcutaneous fat (blue arrow)

Histopathological Changes associated with ND

The microscopic lesions encountered in this study were mostly congestions and haemorrhagic foci in different tissues such as lungs, liver, intestine, trachea and spleen. Other histopathological findings in the lungs were severe multifocal broncho-interstitial pneumonia.

Within the lungs of some of the birds, alveolar lumina were diffusely filled with abundant homogeneous pale eosinophilic fluid (alveolar oedema), macrophages, erythrocytes, or cellular necrotic debris, and in some cases alveoli were collapsed (atelectasis). There were multiple foci of degenerated parabronchial endothelium and lumens were filled with sloughed necrotic epithelial cells as well as karyorrhectic and cellular debris mixed with a few heterophils and macrophages (Plate XI).

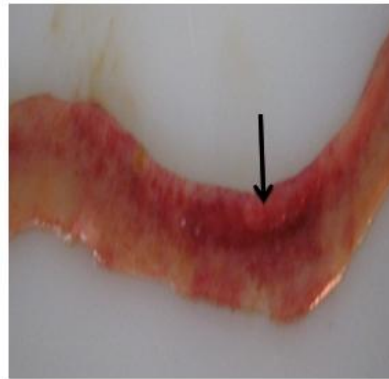


Plate VII: Gross pathological changes in the small intestine of indigenous chicken (*Gallus gallus*). Note the diffuse and coalescing haemorrhagic ulcers in the Jejunum (black arrow)




Plate VIII: Gross pathological changes in the trachea of a Hooded vulture (*Necrosytes monachus*). Note the hyperaemic and congested trachea

There was neuronal degeneration, perivascular lymphocytic infiltration affecting the brain and hyperplasia of vascular endothelium and multifocal gliosis and areas of neuronal necrosis.

Within the neurons there was vacuolation, haemorrhages and intracytoplasmic inclusion bodies (Plate XIII). The myocardium showed severe inflammatory cellular infiltration within muscle fibres and within vessels (Plate XII). There was lymphocytic depletion and haemorrhages of the spleen (Plate XV).

perivascular cuffing (Plates XVI and XVII). There was extensive mononuclear cell infiltration mainly by lymphocytes, in intertubular spaces of the kidneys, indicating characteristics of interstitial nephritis, oedema, haemorrhage as well as congestion (Plates XVIII and XIX). There was also pronounced cellular infiltration of the sub mucosa of the trachea (Plates XX).

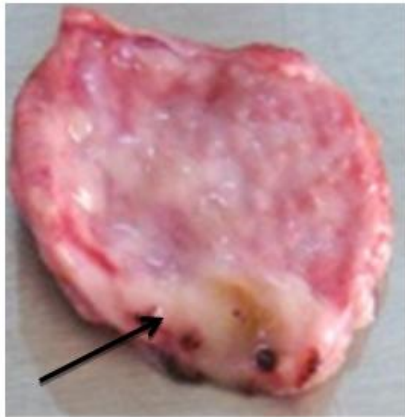


Plate IX: Gross pathological changes in the proventriculus of Cameroon olive pigeon (*Columba sjostedti*). Note haemorrhagic necrotic foci

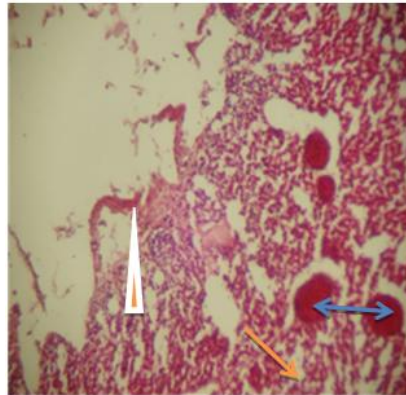


Plate XI: Section of the lung of indigenous chicken. Note the severe congestion (double headed blue arrow), peribronchial and foci of haemorrhages H & E stain x 40

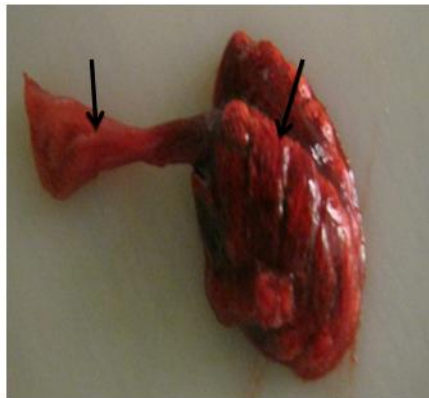


Plate X: Goss pathological changes in the trachea and lungs of Red-eyed-dove (*Streptopelia semitorquata*). Note the congestion of the trachea and the lung (black arrows)

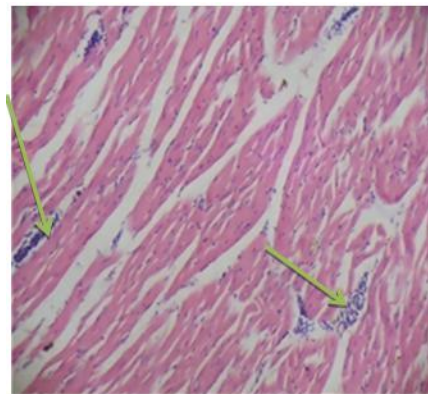


Plate XII: A section from the heart of indigenous chicken (severe Note the marked infiltration between myofibrils myocarditis). H & E stain x 40

Arranged randomly, within the liver were numerous sharply demarcated areas of coagulative necrosis with loss of hepatic architecture and cellular details and replacement by karyorrhectic and cellular debris mixed with abundant fibrin and numerous erythrocytes, these foci were surrounded by lymphocytes-

Immunohistochemical Changes associated with ND

All IHC positive cases (indigenous chickens and Red-eyed-dove) shared similar staining patterns i.e. in proventriculus, spleen, trachea and brain. Strong positive staining was mainly seen in tissues such as spleen, trachea, liver, brain, and

kidneys. Some of the positively stained tissues in this study are presented in Plates XXI- XXIV.

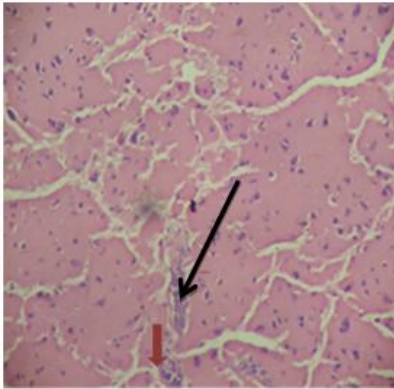


Plate XIII: Section of the brain of indigenous Chicken. Note the congested blood capillaries (black arrow). Red arrows

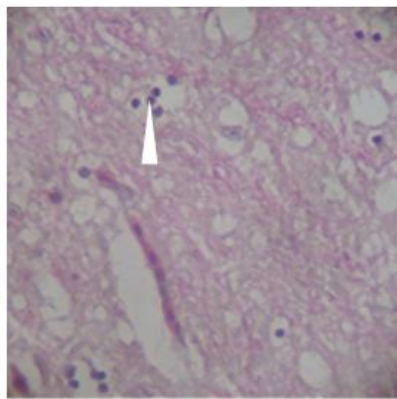


Plate XIV: A section from the indigenous chicken brain. Note the Virchow Robin space (white arrow. H & E stain x 40)

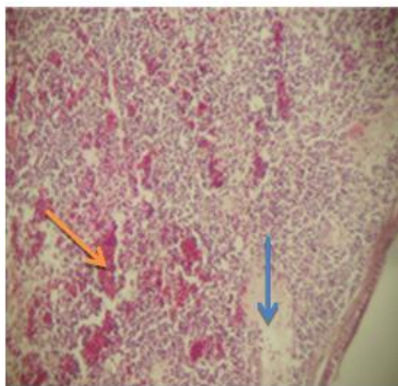


Plate XV: Section of the spleen of indigenous chicken. Note the marked (blue arrow) and fibrin deposits and haemorrhages (yellow arrow) H & E stain x 40

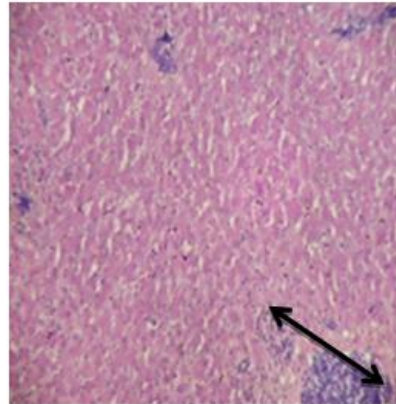


Plate XVI: A section from the liver of indigenous chicken. Note the lymphocytic hepatocellular infiltration (black double headed arrow). H & E stain x 40

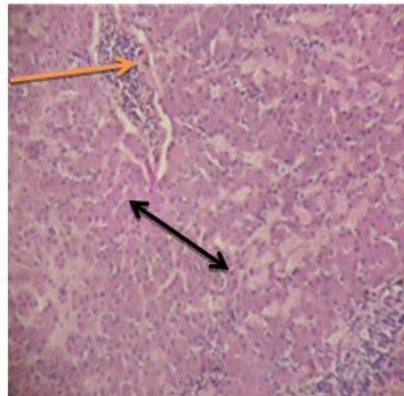


Plate XVII: A section from the liver of red-eyed-dove. Note the perivascular infiltration (yellow arrow) as well as generalized degeneration of sinusoids (black arrow). H & E stain x 40

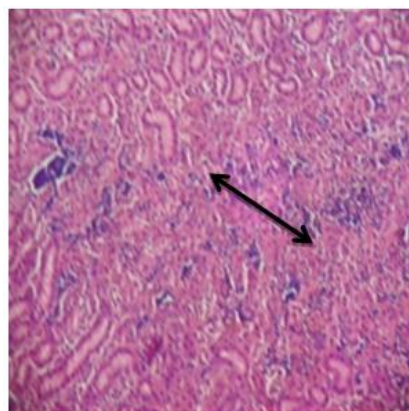


Plate XVIII: Section of the kidney of red-eyed-dove. Note the severe cellular infiltration (black arrow) H & E stain x 40

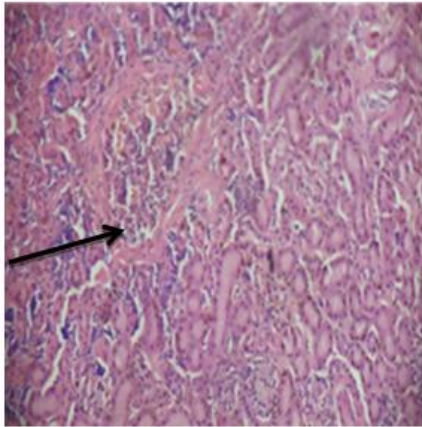


Plate XIX: Section of the kidney of chicken indigenous chicken (*Gallus gallus*). Inflammatory cell infiltration within both interstitial tissue and capillary (black arrow) H & E stain x 40

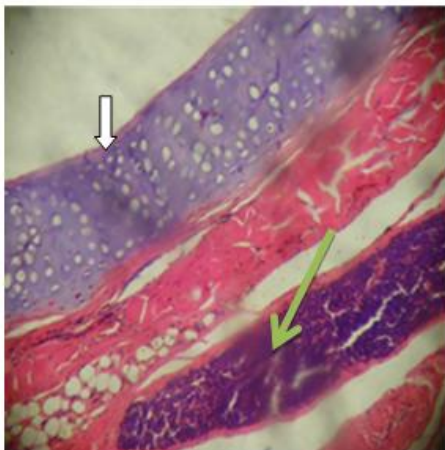


Plate XX: A section from the trachea of indigenous Note the areas of severe lymphocytic cellular infiltration affecting the muscularis layer (green arrow) The mucosa layer (white arrow) is here Completely eroded. H & E x 40

velogenic, mesogenic and lentogenic refer to the mean death time (MDT) <in eggs; while viscerotropic or neurotropic refer to the pathology of the disease produced. Viscerotropism is marked by haemorrhagic gut lesions and neurotropism by nervous signs. [24] In this study, some of the pigeons showed nervous signs, such as paralysis of legs and wings, which were not as severe as those nervous signs previously reported by Khan, El-Mubarak *et al.*, and Mishra *et al.*, [25-27]. The nervous signs observed in pigeons in this study could be due to degenerative lesions observed in their brains histopathologically. Fischer [28] attributed nervous signs in pigeons with ND to degenerative and inflammatory lesions of the nervous system which similar to our findings. No respiratory signs were observed in pigeons in the present study. Fischer [28] also did not observe any respiratory signs in ND field outbreaks or experimentally infected pigeons. The absence of clinical signs of ND in all the ducks sampled is in line with the report of Alexander [6].

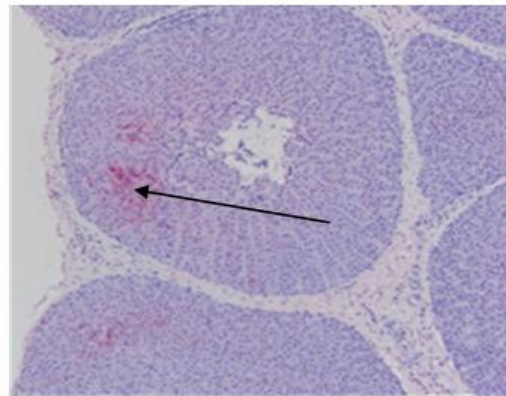


Plate XXI: A section from the proventriculus of Red-Eyed Dove. Note the demonstration of antigen localization on proventricular glands (black arrow) an avidin-biotin Alkaline phosphatase, hematoxylin counter stained. x 40

4. DISCUSSION

Newcastle disease virus is one of the most important infectious agents in the poultry industry. Brown *et al.* [24] reported that the disease signs produced by the different virus strains fall into 4 pathological forms which are describes as: Doyle's form (or viscerotropic-velogenic), Beach's form (or neurotropic-velogenic), Beaudette's form (or mesogenic) and Hitchner's form (or lentogenic). The terms

The gross lesions such as swelling and congestion of the brain, which were present only in few cases of pigeons in the present study, were in congruence with the findings of Khan and Okitai and Mukisira [25,29] and who reported haemorrhages in the brain and mucosa surface of proventriculus and the small intestine of pigeons infected with NDV. However, the findings in this study are contrary to reports of Brown *et al.* [30], who found no gross lesions in pigeons infected with NDV.

In this study, some wild birds, especially the Red-eyed-dove, which were caught alive and observed for ten days showed clinical signs, ranging from weakness, depression, paralysis, and greenish diarrhoea, thus contradicting the findings of Oladele et al., [31,32]. In the latter study on free living wild birds in Zaria, no clinical signs were observed after 2 weeks of monitoring, though very high antibody titre to NDV occurred when heamagglutination inhibition test was used. It was then suggested that these wild birds might harbour some strains of NDV without necessarily showing clinical signs of ND. However, observation of clinical signs in Red-eyed-dove and several other wild birds (vultures, Grey plantain Eater, Barn owl, Sun bird, and Red billed Queler) along with the demonstration of high HI antibody titres in other studies [32], raise concerns about the role of wild birds in NDV transmission. More specifically, synanthropic birds (pigeons, doves, house sparrows) known to associate with poultry farms may contaminate feed and serve as a reservoir of NDV for indigenous chickens study, may suggest a new finding, which indicates a deviation from the report that wild birds harbour NDV without showing clinical signs of the disease [32].

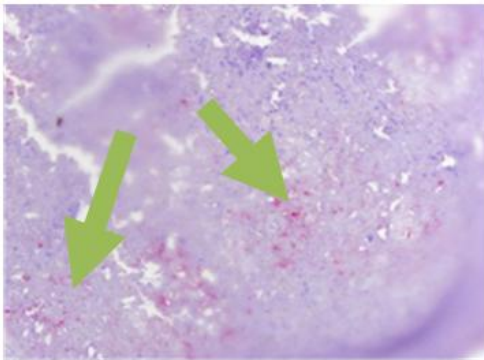


Plate XXII: A section from the spleen of indigenous chicken, Note the positive antigenic staining (green arrow). Avidin–biotin alkaline phosphatase, hematoxylin counter stained. x 40

In this study, gross and histopathological changes of ND were observed in Red-eyed-dove and several other wild birds, such as Vultures, Grey plantain eater, Barn owl, Sun bird and Red billed queler. These findings coupled with the detection of positive immunohistochemical staining of NDV antigen in the tissues of Red-eyed-dove is in agreement with studies indicating high HI antibody titres previously observed in

doves by Oladele et al. [32]. However, observation of clinical signs in Red-eyed-dove in this study, may suggest a new finding, which indicates a deviation from the report that wild birds harbour NDV without showing clinical signs of the disease [32]. The intestinal and lung lesions observed in domestic and wild birds in this study suggest the probable presence of NDV in their organs, and consequently, can enhance shedding of the virus through faecal and nasal routes in the environment. Even though the signs seen in these two organs are not pathognomic for NDV.

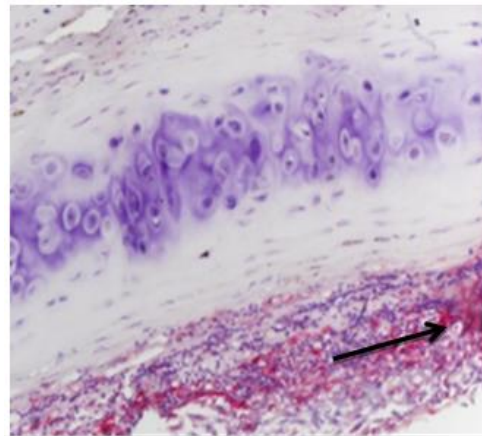


Plate XXIII: A section from the trachea of indigenous chicken Note the positive antigenic stain on the mucosa surface (black arrow). Avidin–biotin alkaline phosphatase hematoxylin counter stain. X 40

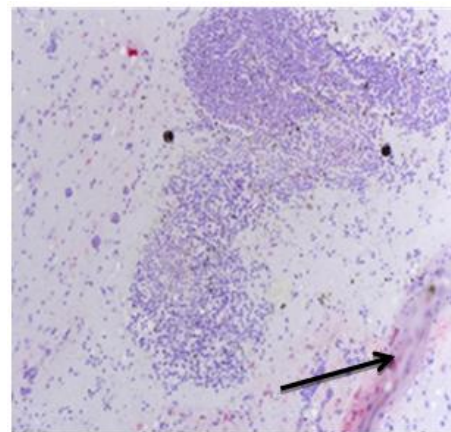


Plate XXIV: A section from the brain of red-eye dove Note the positive antigenic staining (black arrows). Avidin–biotin alkaline phosphatase, hematoxylin counter stain. x 40

Table 3. Summary of the number of the different birds sampled in this study with Clinical signs, gross and histopathological lesions suggestive of Newcastle disease and results of immunohistochemistry (% in parenthesis) in the birds in Plateau State

S/No	Common name of birds	Scientific names of birds	Total No. of birds	No. with CS of ND such as diarrhoea, paralysis, weakness, torticollis	No. without CS suggestive of ND	No. with Gross lesions suggestive of ND such as petechial haemorrhages on abdominal fat, haemorrhages on mucosa surface of proventriculus	No. without Gross lesions suggestive of ND	No. with histo. Lesions suggestive of ND such as vascular congestion, perivascular cuffing, haemorrhages	No. positive for NDV antigen by IHC
1.	Speckled pigeon	<i>Columba guinea</i>	12	5(41.67%)	7(58.33%)	5(41.67%)	7(58.33%)	4(33.33%)	0(0.00%)
2.	Laughing dove	<i>Streptopelia senegalensis</i>	4	3(75.00)	1(25.00)	3(75.00)	1(25.00)	2(50.00)	0(0.00)
3.	Red-eyed-dove	<i>Streptopelia emitorquata</i>	8	3(37.50)	5(62.50)	3(37.50)	5(62.50)	5(62.50)	2(25.00)
4.	Common Bulbul	<i>Pyenonotus barbatus</i>	2	0(0.00)	2(100.00)	1(50.00)	1(50.00)	1(50.00)	0(0.00)
5.	Grey plantain eater	<i>Crinifer piscator</i>	1	1(100.00)	0(0.00)	1(100.00)	0(0.00)	1(100.00)	0(0.00)
6.	Cattle egret	<i>Bulbulcus ibis</i>	2	1(50.00)	1(50.00)	1(50.00)	1(50.00)	1(50.00)	0(0.00)
7.	Barn owl	<i>Tyto alba</i>	3	0(0.00)	3(100.00)	0(0.00)	3(100.00)	0(0.00)	0(0.00)
8.	Hooded vulture	<i>Necrosyite monanachus</i>	6	5(83.33)	1(16.67)	2(33.33)	4(66.67)	3(50.00)	0(0.00)
9.	Variable sun bird	<i>Cinnyris venustus</i>	2	2(100.00)	0(0.00)	1(50.00)	1(50.00)	1(50.00)	0(0.00)
10.	Red-billed fire fincher	<i>Lagonostica senegala</i>	8	8(100.00)	0(0.00)	2(25.00)	6(75.00)	4(50.00)	0(0.00)
11.	Double-spured francolin	<i>Francolinus bicalcaratus</i>	8	0(0.00)	8(100.00)	0(0.00)	8(100.00)	0(0.00)	0(0.00)

12.	Vineaceous dove	<i>Streptopelia vinacea</i>	5	1(20.00)	4(80.00)	1(20.00)	4(80.00)	0(0.00)	0(0.00)
13.	Bronze Mannanikin	<i>Sperestes cucullata</i>	12	0(0.00)	12(100.0)	1(8.33)	11(91.67)	1(8.33)	0(0.00)
14.	Cameroon Olive Pigeon	<i>Columba sjostedti</i>	98	7(7.14)	91(92.86)	6(6.12)	92(93.88)	5(5.10)	0(0.00)
15.	Red-billed Queler	<i>Quela Quelea</i>	12	10(83.33)	0(0.00)	1(8.33)	11(91.67)	1(8.33)	0(0.00)
16.	Weaver bird	<i>Plocaes luteolus</i>	5	0(0.00)	5(100.00)	1(20.00)	4(80.00)	0(0.00)	0(0.00)
17.	Black kite	<i>Milvus migrans</i>	6	6(100.00)	0(0.00)	1(16.67)	5(83.33)	2(33.33)	0(0.00)
18.	Indigenous chicken	<i>Galus galus</i>	349	12(3.44)	337(96.56)	6(1.72)	343(98.80)	6(1.72)	6(1.72)
19.	Domestic ducks	<i>Cairina moscata</i>	96	0(0.00)	96(100.00)	0(0.00)	96(100.00)	0(0.00)	0(0.00)

CS: Clinical signs; Histo: Histopathology; IHC: Immunohistochemistry

The histopathological changes, such as mononuclear cellular infiltration, necrosis, lymphoid depletion, congestion, haemorrhages of the intestine, proventriculus and trachea observed in indigenous chickens and some wild birds in this study are in agreement with results obtained in indigenous chickens, wild birds, pigeons and Japanese quails by Oladele et al., [5,30,32]. The gross and histopathological changes observed in Red-eyed-dove and several other wild birds such as Vultures, Grey plantain eater, Barn owl, Sun bird and Red billed queler in this study, as well as the demonstration of high HI antibody titres previously observed in some of these wild birds by Oladele et al., [32] indeed raise serious concern as these wild birds, particularly the doves are often seen sneaking in and out of commercial poultry farms and always mingling with free-range indigenous chickens during which time they may contaminate feed, water and the environment with NDV [32].

The detection of positive immunostaining of NDV antigens in two of the wild birds (Red-eyed-dove and six of the indigenous chickens is in agreement with reports of Saidu et al., [33] in studies with ducks and geese in China as well as studies of Brown et al., [24] on turkeys in America. Hu et al., [22] also reported the detection of NDV antigens in tissues of Cormorants, Pelicans and Ring billed gulls in Canada.

5. CONCLUSION

Some of the clinical signs, gross and histopathological changes observed in this study, in both indigenous chickens and wild birds are similar to previous results obtained from exotic/commercial chickens infected with NDV. Unless better control measures are exercised, in terms of effective application of vaccines, and movement restrictions involving both infected chickens and human populations during outbreaks, the evolution of new lineages and spread of velogenic NDV strains in Nigeria and indeed the sub-region may continue unabated for a long time to come.

This study discovered velogenic ND strains in indigenous chickens; this discovery can be beneficial for planning of control measures for both exotic and indigenous chickens. This will help researchers to develop vaccines for indigenous chickens. There is slight difference in NDV isolates in this study found in indigenous chickens, from previous isolates in commercial

chickens. The indigenous chickens are known to harbour either lentogenic or mesogenic strains of the NDV. Therefore, this is the first time to the best of our knowledge that the virulent strain of the ND virus is being reported in indigenous chicken using immunohistochemical technique in chickens in Plateau State, Nigeria.

ETHICAL APPROVAL

As per international standard or university standard ethical approval has been collected and preserved by the authors.

ACKNOWLEDGEMENT

Authors wish to acknowledge the contributions of Necropsy attendants, the management committee of the Research Institute where I work, Professor C.C. Brown, of the University of Georgia, who apart from graciously providing me with a comfortable accommodation also granted me the opportunity to use some of their facilities at Zhiang, the technician in the department of Veterinary Pathology for. Drs. Afonso, C. and David Swayne of the SEPRL for willingly accepting my samples and diligently running the molecular aspect of the work.

COMPETING INTERESTS

Authors have declared that no competing interests exist.

REFERENCES

1. Mburu PM, Ondwasy HO. Discover hidden treasure in local chicken. Kenya Agricultural Research Institute (KARI) leaflet. 1999;8:2.
2. Kumbish PR: The reproductive capacity of local chickens in Plateau State, Nigeria, DVM Project Work. 1989;3-4.
3. Okitoi LO, Mukisira EA. The potential on-farm impact of appropriate technologies on productivity of indigenous chicken in western Kenya. Testing of Livestock Technologies on Small Holder Mixed Farms in Kenya; 2002.
4. Nenkare J, Ondwasy HO. The contribution of scavenging indigenous chicken to the socio economic welfare of the rural households. Proceedings KARI Scientific Conference. KARI Headquarters, Nairobi Nov. 2002;7-9.
5. Oladele SB, Kazeem HM, Raji MA. Survey for antibodies to infectious bursal disease,

- Newcastle disease and fowl pox in ducks, pigeons and guinea fowls in Zaria. Nigerian Veterinary Journal. 1996;1:85-87.
6. Alexander DJ. Newcastle disease and other avian paramyxoviruses. *Revue Scientifique et Technique – Office International des Epizooties*, 2000;19:443–462.
 7. Oladele SB, Nok AJ, Esievo KAN, Abdu P, Useh NM. Haemagglutination inhibition antibodies, rectal temperature and total protein of chickens infected with a local Nigerian isolate of velogenic Newcastle disease virus. *Veterinary Research Communication*. 2005;29:171-217.
 8. Hill CD, Davies OS, Wilde JK. Newcastle disease in Nigeria. *British Veterinary Journal*. 1953;381-385.
 9. Ezeokoli CD, Umoh JU, Adesiyun AA, Abdu PA. Prevalence of newcastle virus antibodies in local and exotic chickens under different management systems in Nigeria. *Bulletin Animal Health Production for Africa*. 1984;32:253-257.
 10. Fatumbi OO, Adene DF. Susceptibility of the Nigerian local chickens to a fulminating newcastle disease outbreak. *Nigerian Veterinary Journal*. 1979;8:30-32.
 11. Abdu PA, George JB., Umoh JU. A study of poultry disease diagnosed at Zaria from 1981-1984. *Nigerian Veterinary Journal*. 1985;14:63-65.
 12. Gomwalk NE, Adesiyun JT, Bishu G, Adesuyun AA. A serological survey of Newcastle disease virus in domestic poultry around Zaria. *Nigerian Veterinary Journal*. 1985;14:70.
 13. Manchang TK, Abdu PA, Sa'idu L. Epidemiology and clinico-pathologic manifestations of Newcastle disease in Nigerian local chickens. *Review Elsevier Medicine Veterinary Pays Tropical*. 2004;57(1-2):35-39.
 14. Plateau State Ministry of Agriculture, Avian Influenza Control Office. Poultry farm census and Poultry population census, Quarterly Bulletin. 2008;1:5-35.
 15. Alexander DJ, Wilson GWC, Russell PH, Lister SA, Parsons G. Newcastle disease outbreaks in fowl in Great Britain during 1984, *Veterinary Records*. 1985;117:429-434.
 16. Cherdchai R. Study of the Newcastle disease vaccination one to four times a year in native chickens raised in the village. *Thai Journal of Veterinary Medicine*. 1988;18:3-5.
 17. National Population Commission (NPC). Plateau State Statistics Tables, Head office Abuja, Nigeria. 2006;12-18.
 18. National Fadama Development Project (NFDP): Plateau Agricultural Development Project, Quarterly Review Bulletin. 2009;4-9.
 19. Oladele SB, Enoch I, Sa'idu L, Ibu OJ. Clinico-pathological features of newcastle disease in Japanese quails (*Coturnix coturnix japonica*) infected with newcastle disease virus Kudu 113 Strain, *International Journal of Poultry Science*. 2008;7(2):165-168. Asian Network for Scientific Information, 2008 ??
 20. National Remote Sensing Corporation Jos. Classified geo sensing data for Plateau State, Nigeria. National Remote Sensing Head Office, Jos, Plateau, Nigeria; 2008.
 21. Awwiuro OG. Staining reactions of microwave processed tissues compared with conventional paraffin wax processed tissues. *European Journal of Experimental Biology*. 2011;1(1):57-62.
 22. Hu BX, Wu YT, Liu XF. Monoclonal antibodies with specificity to different epitopes of the fusion protein of Newcastle disease virus. *Acta Veterinaria et Zootechnica Sinica (In Chinese)*, 2003;34:216-222.
 23. Sa'idu L, Abdu PA, Tekdek LB, Umoh JU, Usman M, Oladele SB. Newcastle disease in Nigeria. *Nigerian Veterinary Journal*. 2006;27:23-32.
 24. Brown CC, Pacenti AM, King GD, Seal BS, Zhang J. Pathogenesis of newcastle disease in commercial and specific pathogen-free Turkeys experimentally infected with isolates of different virulence. *Veterinary Pathology*. 2006;43:168-178.
 25. Khan MA. Epizootiology of newcastle disease in wild birds. M.Sc. Thesis. Department of Microbiology, University of Agriculture, Lyallpur. 1968;56-69.
 26. El-Mubarak AK, Elzein EEEA, Elgasim AIA, Abu Elzein EME, Elgasim AIA. Note on the pathology of experimental infection of pigeons by the pigeon paramyxovirus type-1 (PPMV-1). *Revue d'Elevage-et-de-Medicine Veterinary Des-Pays-Tropican*, 1990;43:441-444. (*Veterinary Bulletin*, 1870,1992;62:).
 27. Mishra S, Kataria JM, Sah RL, Verma KC, Mishra JP. Studies on the pathogenicity of Newcastle disease virus isolates in guinea

- fowl. Tropical Animal Health Production. 2001;33:313-20.
28. Fischer E. Pathology of spontaneous paramyxovirus-1 infection in pigeons. Inaugural-Dissertation Fachbereich Veterinärmedizin Justus-Liebig-Universität, Giessen, German Federal Republic. 1986;84. (Poultry Abstract. 13: 1917, 1986)
29. Okitoyi LO, Mukisira EA. Improved management of indigenous chicken. KARI Technical Note No. 8; 2001.
30. Brown CC, Ecco R, Susta L, Cagle C, Cornax I, Pantin-Jackwood M, Miller PJ, Afonso CL. *In vivo* transcriptional cytokine responses and association with clinical and pathological outcomes in chickens infected with different newcastle disease virus isolates using formalin-fixed paraffin-embedded samples. Veterinary Immunology and Immunohistochemistry. 2011;141(3-4):221-9. DOI: 10.1016/Journal of Veterinary Immunology.2011.03.002, 2011
31. Oladele SB, Enam SJ, Okubanjo OO. Pathogenic haemoparasites and Antibody to newcastle disease virus from apparently healthy wild birds in Zaria, Nigeria. Veterinary World. 2012;5(1):13-18.
32. Oladele SB, Morou M, Ibrahim NDG, Sambo SJ, Ibu JO. Susceptibility of pigeons (*Columbia livia*) to velogenic newcastle disease virus strain isolated from Duck. Zaria Veterinarian. 2011;8(1): 16-21.
33. Sa'idu L, Abdu PA, Markus EL. Retrospective studies on Newcastle disease in vaccinated flocks in Zaria, Nigeria. Student Veterinarian. 1998;17:27-31.

© 2019 Rinle et al.; This is an Open Access article distributed under the terms of the Creative Commons Attribution License (<http://creativecommons.org/licenses/by/4.0>), which permits unrestricted use, distribution, and reproduction in any medium, provided the original work is properly cited.

Peer-review history:
The peer review history for this paper can be accessed here:
<http://www.sdiarticle3.com/review-history/49616>