



Os Acromiale-unusual Manifestation as Superior Spur and Bursitis-A Case Report

**A. Raviraj¹, Vidyasagar Maalepati², K. Abhishek Sugumar²,
Vivek Kumar N. Savsani², Ajith K. Prabhu² and Ashish Anand^{2*}**

¹Apollo Hospitals, Bannerghata Road, Bangalore-560076, India.

²VAMC Jackson, University of Mississippi Medical Center, Jackson, Prof William Carey School of Osteopathic Medicine, Hattiesburg, MS, USA.

Authors' contributions

This work was carried out in collaboration among all authors. Authors AR, VM and AA designed the study, performed the statistical analysis, wrote the protocol and wrote the first draft of the manuscript. Authors AS, VKNS, AKP and VM managed the analyses of the study. Authors AR, AA managed the literature searches. All authors read and approved the final manuscript.

Article Information

DOI: 10.9734/JAMMR/2019/v31i230284

Editor(s):

(1) Dr. Panagiotis Korovessis, Chief Orthopaedic Surgeon, Orthopaedic Department, General Hospital "Agios Andreas" Patras, Greece.

Reviewers:

(1) Mohit Kumar Patralekh, Vardhman Mahavir Medical College, India and Guru Gobind Singh Indraprastha University, India.
(2) K. Saravanan, PSG College of Physiotherapy, India.

Complete Peer review History: <http://www.sdiarticle4.com/review-history/52642>

Case Report

Received 15 September 2019

Accepted 18 November 2019

Published 22 November 2019

ABSTRACT

An Os acromiale is a condition that results from the failure of fusion of the anterior acromial apophysis. It can be asymptomatic. It can also result in subacromial impingement and rotator cuff tear. In this case report of a 39 year-old lady we would like to present the management of the painful bursitis and spur formation on the superior surface of a meso-type of os acromiale. Conservative management in the form of rest, anti-inflammatory drugs and physiotherapy did not provide symptomatic relief. Patient then underwent surgical excision of the superior spur. Open reduction and internal fixation was not carried out. Patient had resolution of pain and no recurrence of symptoms or features of impingement at 6 months follow up. To the best of our knowledge there are *limited reports* in English literature about this rare subset of patients with symptomatic os acromiale with superior spur formation and with no features of impingement or cuff pathology.

*Corresponding author: E-mail: ashishanandortho@yahoo.com;

Keywords: Superior spur; bursitis; acromial apophysis; anti-inflammatory drugs.

1. INTRODUCTION

The incidence of Os acromiale has been reported ranging from 1 to 15%. Bilateral involvement is seen in 41 to 62% of cases [1-3].

Os acromiale is a developmental anomaly characterised by *absence* of an osseous union between the ossification centres of the acromion, resulting in a fibrocartilaginous tissue connection. The centres of ossification include pre acromion, Meso acromion and meta acromion. The various centres ossify by 18-25 years of age. The clinical implication of this is that diagnosis can only be made beyond age 25 [1]. The usual presentation is asymptomatic radiographic finding or a traumatic event causing onset of clinical symptoms [2-6]. Patients are initially treated with Non-surgical modalities and surgical treatment is reserved for situations for patient's refractory to non surgical modalities. Only after nonsurgical management has failed to relieve symptoms. Numerous treatments have been proposed including open or arthroscopic excision of the os fragment [6,7], open reduction and internal fixation (ORIF) with or without bone grafting [8-13] arthroscopic subacromial decompression with acromioplasty [10,14-17] and arthroscopically assisted reduction-internal fixation [18]. Williams, et al. [19] have reported a new technique for symptomatic meso-acromiale- this involves removal of segment of bone between the two ends of os-acromiale.

Symptomatic patients usually present with impingement and rotator cuff tears [20] and are usually of the meso-acromion subgroup [20,21].

This paper reports a case of unilateral mesoacromion presenting with severe shoulder pain, had spur formation and bursitis on the superior surface of the acromion, without any features of the subacromial impingement or cuff tear. Authors describe surgical management of such a case along with the clinical features, imaging and a brief review of literature.

2. CASE REPORT

A 39 year old lady, right hand dominant, presented to the Outpatient clinic with complaints of pain in the right shoulder for 4 weeks. She reported worsening of symptoms on overhead activities. Patient denied any history of trauma or history of similar complaints in the past. Patient had not received any treatment for these symptoms prior to presentation.

Clinical examination revealed normal muscle bulk bilaterally. A bony hard projection was noted over superior aspect of the lateral border of the acromion. Digital pressure over the acromion was *painful*. Forward flexion and abduction of the shoulder was painful. Neer's and Hawkin's test for impingement were negative. Jobe's test for supraspinatus and Speed test for biceps were negative.

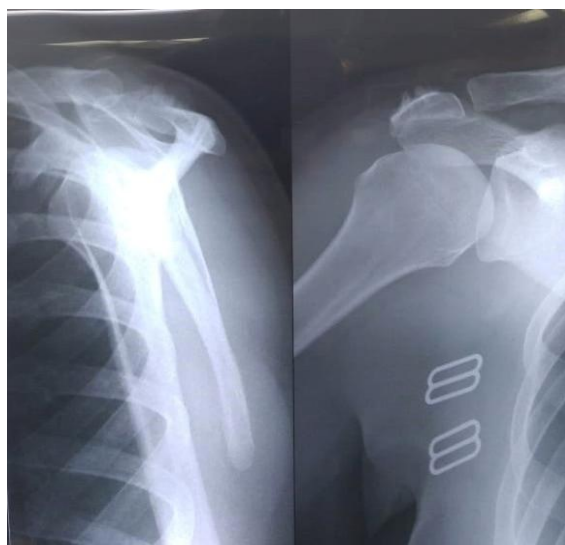

Fig. 1. X-ray showing Os acromiale and superior spur

Routine AP and axillary projections of the shoulder revealed normal subacromial space and a meso type of os acromiale (Fig 1). No degenerative changes were noted in the AC joint. CT confirmed the meso type of os acromiale with bony spurs over the superior surface on either side of the pseudo arthrosis (Figs. 2 and 3). MRI of the shoulder joint was done, which showed no evidence of rotator cuff tear (Figs. 4 and 5).

Patient was initially treated conservatively with analgesics and targeted physical rehabilitation programme for 12 weeks. In view of a failed trial

of conservative treatment, patient was advised surgical intervention. In beach chair position, using a lateral approach the left acromion was exposed. The bony spurs over the superior surface of the acromion were noted and excised using a saw and the surface smoothed with a burr (Figs. 4 and 5). The site of the *os acromiale* was examined, which showed minimal movement. Decision was taken not to excise the fragment due the risk of deltoid weakness. ORIF was not undertaken in view of minimal movement at pseudarthrosis site and no evidence of cuff pathology.

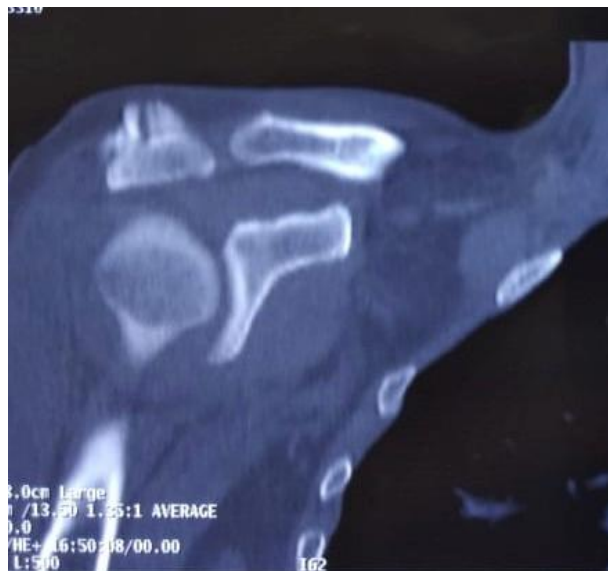

Fig. 2. Ct Scan showing superior spur

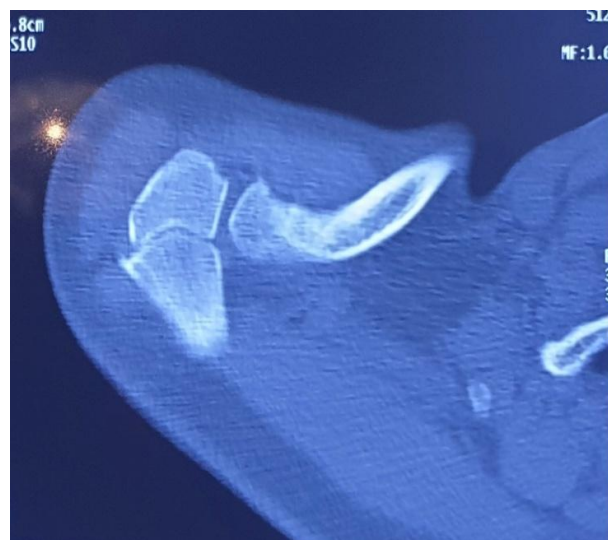

Fig. 3. Ct Scan showing OS Acromiale

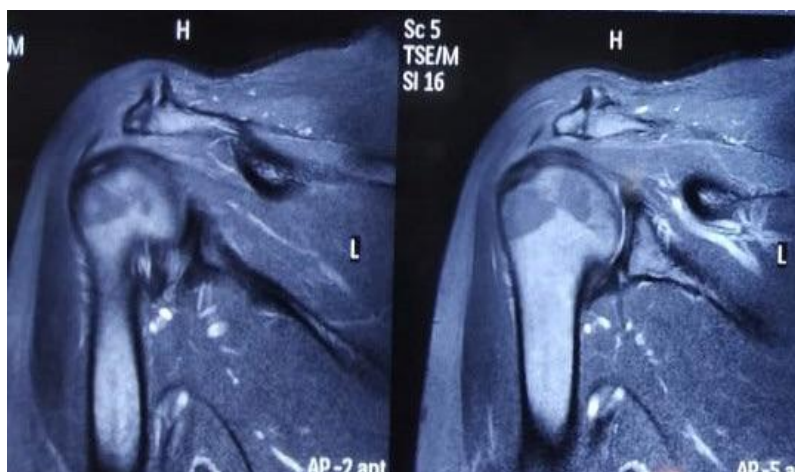


Fig. 4. MRI showing superior spur and no evidence of cuff tear

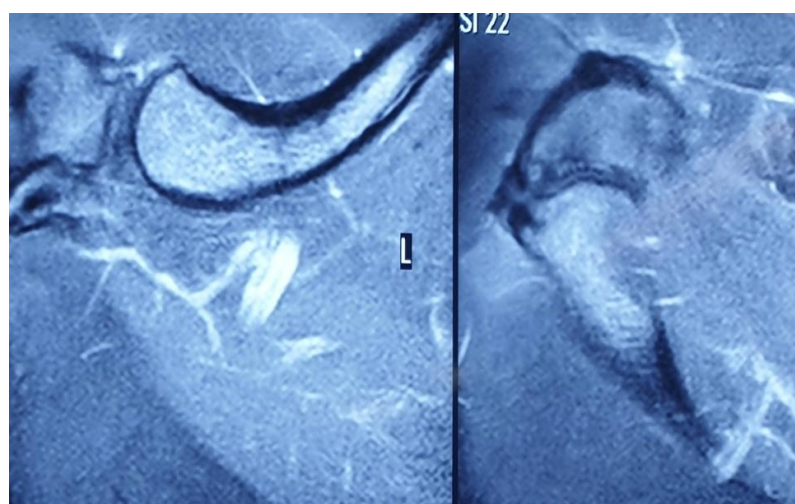


Fig. 5. Axial MRI showing Os Acromiale

3. DISCUSSION

Gruder was the first one to report Os acromiale. Prevalence of os acromiale has been reported in 1% to 30% of the general population, with 41% to 62% of cases presenting with bilateral involvement [1-3].

The acromion develops from three ossification centres, referred to as pre, meso and meta acromion recognizable from the eighteenth year of life. Initially the meta acromion fuses to the scapula and the preacromion and mesoacromion fuse to each other. All three centres finally fuse to the scapula by the twenty-first to twenty-fifth year of life [20-23]. In situations where these centres fail to finish the process of ossification it results in Os Acromiale [22-24].

Some authors have suggested the area of pseudo arthrosis in vicinity of Ac Joint alters function of the acromioclavicular joint and in the presence of an os acromiale as a cause of impingement syndrome and full thickness rotator cuff tears (Williams, et al. [20]. Atoun, et al. [18] in a prospective study in 2016 proposed the role of os acromiale in the pathophysiology of massive rotator cuff tears-however our patient did not have any rotator cuff tear.

The initial treatment of symptomatic Os acromiale is conservative which involves subacromial steroid shot and physical therapy [13]. The optimal surgical treatment option in a patient with a symptomatic os acromiale following a trial of conservative treatment is controversial. Prunell, et al. in a systematic

review compared the outcomes of three surgical strategies used. The options included for review were excision, acromioplasty and open reduction and internal fixation. The observed higher patient satisfaction results in excision and ORIF group compared to acromioplasty group. Highest complication rate was noted in ORIF group with a need for second elective procedure for removal of hardware [26]. Fragment excision has been reported to have complication of deltoid weakness [27]. New technique has been reported by Williams et al where by segment of bones is removed between the two fragments and is combined with acromioplasty. They reported their observations on six patients with excellent outcomes. The basis for their treatment was arthroscopic partial resection of the acromial non-union site minimizes any contact between the two fragments which is believed to be a pain generator. When this is combined with acromioplasty that also removes external impingement as source of pain. In their short series *all* patients had resolution of the point tenderness over the os- acromiale and none developed any complications, including painful instability of either the anterior os fragment or the acromioclavicular joint.

Our case involved a patient with a symptomatic meso type of os acromiale without features of external impingement or rotator cuff tear. Also in our case the spur was superior and not inferior. Patient underwent surgical excision of the spurs over the superior surface of the acromion. In view of minimal movement at the interacromial joint, further intervention in the form of excision of the fragment or ORIF was not carried out. It is difficult to explain why spur formed superiorly and not inferiorly, the most plausible explanation would be more stress at non-union site superiorly. Bursa formation was protective in nature secondary to irritation by the superior spur. Irritation of bursa secondary to spur was the cause of pain and excision of spur resulted in resolution of the symptoms. At one year follow up patient had complete symptomatic relief with no wound complications or need for repeat intervention.

The authors would like to propose bursitis over the superior surface of the acromion secondary to spur formation as a cause of intractable shoulder pain in this patient. In our case with these features, spur excision and smoothing of edges provides symptomatic relief. This rare subgroup of patients did not require any additional procedures such as acromioplasty, as

there were no features of impingement. The rotator cuff was intact. There was no need to perform any open reduction in this case, thereby reducing any risk of complications such as deltoid weakness, hardware prominence and a possible second surgery with symptomatic non-union.

4. CONCLUSION

To conclude our case was unique presentation of superior spur formation with associated bursitis adjacent to mesoacromion. Patient did not have rotator cuff tear/external impingement or abnormal mobility at the site of os acromiale. To the best of our knowledge we did not come across a report in English literature of superior spur formation with bursitis in mesoacromiale.

CONSENT AND ETHICAL APPROVAL

As per university standard guideline participant consent and ethical approval has been collected and preserved by the authors.

COMPETING INTERESTS

Authors have declared that no competing interests exist.

REFERENCES

1. McClure JG, Raney RB. Anomalies of the scapula. Clin Orthop Relat Res 1975;110: 22-31.
2. Sammarco VJ. Os acromiale: Frequency, anatomy, and clinical implications. J Bone Joint Surg Am. 2000;82:394-400.
3. Burkhart SS. Os acromiale in a professional tennis player. Am J Sports Med. 1992;20:483-484.
4. Peckett WR, Gunther SB, Harper GD, et al. Internal fixation of symptomatic os acromiale: a series of twenty-six cases. J Shoulder Elbow Surg. 2004;13:381-385.
5. Swain RA, Wilson FD, Harsha DM. The os acromiale: Another cause of impingement. Med Sci Sports Exerc. 1996;28:1459-1462.
6. Edelson JG, Zuckerman J, Hershkovitz I. Os acromiale: anatomy and surgical implications. J Bone Joint Surg Br. 1993; 75:551-555.
7. Mudge MK, Wod VE, Frykman GK. Rotator cuff tears associated with os acromiale. J Bone Joint Surg Am. 1984;66:427-429.
8. Demetracopoulos CA, Kapadia NS, Herickhoff PK, et al. Surgical stabilization of os acromiale in a fast-pitch softball

- pitcher. Am J Sports Med. 2006;34:1855-1859.
9. Hertel R, Windisch W, Schuster A, et al. Transacromial approach to obtain fusion of unstable os acromiale. J Shoulder Elbow Surg. 1998;7:606-609.
 10. Sahajpal D, Strauss EJ, Ishak C, et al. Surgical management of os acromiale: a case report and review of the literature. Bull NYU Hosp Jt Dis. 2007;65:312-316.
 11. Kurtz CA, Humble BJ, Rodosky MW, et al. Symptomatic os acromiale. J Am Acad Orthop Surg. 2006;14:12-19.
 12. Ryu RK, Fan RS, Dunbar WH. The treatment of symptomatic os acromiale. Orthopedics. 1999;22:325-328.
 13. Warner JJ, Beim GM, Higgins L. The treatment of symptomatic os acromiale. J Bone Joint Surg Am. 1998;80:1320-1326.
 14. Jerosch J, Hepp R, Castro WH. An unfused acromial epiphysis. A reason for chronic shoulder pain. Acta Orthop Belg. 1991;57:309-312.
 15. Hutchinson MR, Veenstra MA. Arthroscopic decompression of shoulder impingement secondary to os acromiale. Arthroscopy. 1993;9:28-32.
 16. Wright RW, Heller MA, Quick DC, et al. Arthroscopic decompression for impingement syndrome secondary to an unstable os acromiale. Arthroscopy. 2000;16:595-599.
 17. Harris JD, Griesser MJ, Jones GL. Systematic review of the surgical treatment for symptomatic os acromiale. Int J Shoulder Surg. 2011;5:9-16.
 18. Atoun E, Van Tongel A, Narvani A, et al. Arthroscopically assisted internal fixation of the symptomatic unstable os acromiale with absorbable screws. J Shoulder Elbow Surg. 2012;21:1740-1745.
 19. Johnston PS, Paxton ES, Gordon V, Kraeutler MJ, Abboud JA, Williams GR. Os acromiale: a review and an introduction of a new surgical technique for management. Orthop Clin North Am. 2013;44(4):635-44. DOI: 10.1016/j.ocl.2013.06.015
 20. Granieri GF, Bacarini L. A little-known cause of painful shoulder: Os acromiale. European radiology. 1998;8(1):130-3.
 21. Gruber W. Über die arten der Acromialknochen und accidentellen Acromialgelenke. Arch Anat Physiol Und wissensch Med. 1863;24:373-378.
 22. Grant JC. Baltimore (MD): Williams & Wilkins. 1972;40.
 23. Liberson F. Os acromiale: A contested anomaly. J Bone Joint Surg. 1937;19:683-689.
 24. Nicholson GP, Goodman DA, Flatow EL, et al. The acromion: Morphologic condition and age related changes. A study of 420 scapulas. J Shoulder Elbow Surg. 1996;5: 1-11.
 25. Park JG, Lee JK, Phelps CT. Os acromiale associated with rotator cuff impingement: MR imaging of the shoulder. Radiology. 1994;193(1):255-7.
 26. Purnell JA, Bourget-Murray J, Kwapisz A, Bois AJ, Le Blanc J. Clinical results and complications following surgical management of symptomatic os acromiale: A systematic review. Journal of Orthopaedic Surgery and Research. 2019; 14(1):26.
 27. Neer CS. 2nd. Anterior acromioplasty for the chronic impingement syndrome in the shoulder. J Bone Joint Surg Am. 1972; 54(1):41-50.

© 2019 Raviraj et al.; This is an Open Access article distributed under the terms of the Creative Commons Attribution License (<http://creativecommons.org/licenses/by/4.0>), which permits unrestricted use, distribution, and reproduction in any medium, provided the original work is properly cited.

Peer-review history:
The peer review history for this paper can be accessed here:
<http://www.sdiarticle4.com/review-history/52642>