



A Prospective Study on Functional Outcome of Open Reduction and Internal Fixation of Acetabular Fractures

Venkata Kiran Pillella¹ and J. Lionel John^{1*}

¹*Department of Orthopaedics, Sree Balaji Medical College and Hospital / BIHER, No: 7, CLC Works Road, Chromepet, Chennai – 44, India.*

Authors' contributions

This work was carried out in collaboration between both authors. Both authors read and approved the final manuscript.

Article Information

DOI: 10.9734/JPRI/2020/v32i1330597

Editor(s):

(1) Dr. Mohamed Fathy, Assiut University, Egypt.

Reviewers:

(1) Vijaya Krishnan, MGM College of Physiotherapy, Maharashtra University of Health Sciences, India.

(2) Preksha Barot, GMERS Medical College Himmatnagar, India.

Complete Peer review History: <http://www.sdiarticle4.com/review-history/54216>

Original Research Article

Received 20 May 2020
Accepted 25 July 2020
Published 06 August 2020

ABSTRACT

The current study is a prospective study on the functional outcome of open reduction and internal fixation of acetabular fractures. About 30 patients were analyzed for the functional outcome of acetabular fractures treated by open reduction and internal fixation over a period of one year and eight months from March 2017 to October 2018 with a minimum follow up period of 9 months at Sree Balaji Medical College & Hospital, Chromepet, Chennai. The mean age of the patient was 37.96 year ranging from 20 - 60 years. The Joel Matta score was used for calculation of radiological outcome of 30 patients. The results were excellent in 19 (66.3%), good in 8 (26.6%), fair in 3 (10%), and poor in 0 (0%) patients. Functional outcome of displaced acetabular fractures more than 2 mm displacement was found to have excellent results on open reduction and internal fixation.

Keywords: Acetabular fracture; internal fixation; open reduction; radiological assessment.

1. INTRODUCTION

Acetabular fractures are the injuries which are quite challenging for the orthopaedic surgeon because of their low incidence and their deep & complex anatomy [1]. They are growing in developing countries with the increasing incidence of high energy trauma [2,3].

Fractures of the acetabulum are as a result from high-impact falls or motor vehicle accidents that transmit force most commonly from an impact to the greater trochanter or the flexed knee [4,5]. In younger individuals, High energy trauma is the primary cause of acetabular fractures. Most common type of fractures are posterior wall fractures accounting for approximately 25% of all acetabular fractures [4,5,6] & fractures of anterior wall are rare which constitute only 1% to 2% of all acetabular fractures [4,5]. Fractures of the acetabulum which occur in association with other fractures will influence management options, surgical approach and clinical outcomes [7].

Management of the acetabular fractures is a complex entity in orthopaedics that is being continually refined. It involves a definite learning curve [8]. The surgical management of acetabular fractures has been rapidly evolved over the past three decades, leading to decreased morbidity and improved outcome [9-13]. To a greater extent, this can be attributed to the revolutionary techniques introduced by Judet and Letournel [4,9,14].

Previously most acetabular fractures were treated by closed reduction [14]. Currently, open reduction and internal fixation is considered to be the gold standard treatment for displaced acetabular fractures, as restoration of joint congruity is of supreme importance to reduce the incidence of early hip osteoarthritis [15]. Factors including patient age, general medical condition and associated injuries must be considered before making definitive management decision [16]. The goals of treatment should be anatomic restoration of the articular congruity and early mobilization [8].

In view of increase in road traffic accidents in our country, multiple complex injuries of the acetabulum are noted, hence the need for detailed evaluation and the study for a better functional outcome for acetabular fractures remains a growing challenge for the surgeons. In this study of acetabular fractures we decided to

enrich the knowledge of open reduction and internal fixation for these types of acetabular fractures.

2. METHODS

The present study is a prospective study done in 30 patients to analyze the functional outcome of acetabular fractures treated by open reduction and internal fixation over a period of one year and eight months from March 2017 to October 2018 with a minimum follow up period of 9 months at Sree Balaji Medical College & Hospital, Chromepet, Chennai. The recruitment of patients was from March 2017 to February 2018 (12 months).

2.1 Inclusion Criteria

- Age group greater than 20 yrs and less than 60 yrs of age.
- Closed fractures.
- Patients with fractures less than 3 wks duration.
- All clinically and radiologically proven acetabular fractures having indication of operative treatment.
- Acetabular fractures with displacement > 2 mm.

2.2 Exclusion Criteria

- Fractures in age group less than 20 yrs or greater than 60 yrs of age.
- Compound fractures.
- Patients with fractures greater than 3 weeks duration.
- Pathological fractures.
- Patients with medical contraindications for surgery.
- Undisplaced fractures or minimally displaced fractures < 2 mm.
- Patients with severe soft tissue injury like Morel Lavallee lesion.

In my study, on receiving the patients in emergency room, general assessment and resuscitation was done as per ATLS protocol. After stabilization of vital parameters, complete skeletal survey and associated injuries especially vascular and nerve injuries was assessed. Radiological assessment was done with AP, Judet views of acetabulum and Computed tomography with 3D reconstruction of acetabulum. In all dislocated patients closed

reduction was done under i.v sedation and skeletal traction was applied in all patients.

Open reduction and internal fixation was done within 5-7 days of injury. After completing clinical and radiological examination preoperative planning regarding approach and implant to be used was made on basis of fracture type, displacement and associated injuries.

Medicine and cardiology opinion was obtained, prior to getting anaesthesia fitness. All patients were started on broad spectrum 3rd generation cephalosporins half an hour before the surgery.

All acetabular fractures except both column fractures, the standard fracture reduction sequence is to first to reduce and stabilize the displaced column, if present and then reduce any wall fracture then may be present. After definitive fixation of the reduced fragments, the entire construct is stabilized with locking reconstruction plates.

For the both column fractures the sequence is to first reduce and stabilize one of the columns to the axial skeleton, then the other column, if present, the wall component. After definitive fixation of the reduced fragments the entire construct is stabilized with locking reconstruction plates.

In posterior approach, Schanz pins are placed in greater trochanter, ischial tuberosity and iliac crest for simultaneous manipulation. Various reduction clamps are available to facilitate reduction and holding.

In anterior approach, a Fara beuf clamps or a Schanz pin is placed into iliac crest to manipulate and facilitate reduction.

Mattas quadrangular clamps of various sizes and with offsets and Picador ball spike pusher are used. Reduction fixed with lag screws whenever possible. Lagging is done with 4mm cancellous screws or 3.5mm cortical screw with washer. 3.5mm reconstruction plates are used as neutralization plates.

Spinal or General anaesthesia is usually employed. The position of the patient can be either prone or in the lateral decubitus position on a fracture table or with the leg free according to the procedure planned.

The surgical exposure that affords the best opportunity to restore the joint congruency by anatomic reconstruction and stabilization of the articular surface was selected [17].

The main stay surgical approaches to the acetabulum are those described by Leutournel and Judet: a) The Kocher-Langenbeck Approach, b) The Ilioinguinal Approach, c) The Iliofemoral Approach, and d) The Extended Iliofemoral Approach.

The first three approaches provide direct access to only one column of the acetabulum (Posterior for the Kocher-Langenbeck; Anterior for the Ilioinguinal and Iliofemoral) and rely on indirect manipulation for reduction of any fracture lines that traverse the opposite column. The Extended ilio-femoral approach affords complete direct access to all aspects of the acetabulum. It is most often used for delayed treatment of an associated fracture type in which healing precludes indirect manipulation.

2.3 Postoperative Protocol

- All patients were given pre-operative antibiotics and post-operatively for 5 days of intravenous antibiotics and then 10 days of oral antibiotics.
- First dressing with drain removal done after 48 hrs, second on 5th Post-op day, third on 8th Post-op day.
- Low molecular weight heparin was given 7 days for DVT prophylaxis.
- Indomethacin is given in a dose of 25mg TDS daily beginning within 24 hours of surgery and continued for 4 to 6 weeks.
- Passive mobilization was started on post-operative day2. Active movements started gradually in accordance with pain.
- Suture removal done on 12th to 14th post-operative day.
- Radiological and Functional examination was done on monthly review for first 6 months and third monthly thereafter.
- Gentle hip ROM and non-weight bearing walking was started after 6 weeks. Weight bearing was gradually started after 12 weeks. Partial weight bearing was allowed initially and full weight bearing was not allowed until evidence of complete radiological union.

The patients in the study were analysed by the Matta's radiographic assessment postoperatively

and Modified Merle d'Aubinge and Postel Clinical Grading System at each follow-up.

In Modified Merle d'Aubinge and Postel clinical grading system, pain, gait and range of motion of the hip are assessed and a maximum score of 6 points are given for each. The three individual scores are summed up to derive the final clinical score. This score is classified as excellent (18 points), good (15,16 or 17 points), fair (13 or 14 points) or poor (< 13 points).

Matta's criteria was used to assess the radiological outcome which includes 3

parameters - osteophytes, joint space narrowing & sclerosis. Based on which it has been graded as excellent, good, fair & poor.

The statistical analysis of the data was performed with the use of SPSS software (version 24, SPSS Inc., Chicago, IL, USA). Frequencies, Chi sq test was used to analyse the patients clinical, functional and radiological outcomes. The relationship between type of fracture and clinical (Modified Postel Merle d'Aubigné score) score and radiological (Matta's) outcome was analysed. P-value less than 0.05 was considered significant.

Table 1. The modified merle d'Aubinge and postel clinical grading system [18]

Parameter	Points
Pain	
None	6
Slight or intermittent	5
After walking but resolves	4
Moderately severe pain but patient is able to walk	3
Severe, prevents walking	2
Walking	
Normal	6
No cane but slight limp	5
Long distance with cane or crutch	4
Limited even with support	3
Very limited	2
Unable to walk	1
Range of motion ^a	
95-100%	6
80-94%	5
70-79%	4
60-69%	3
50-59%	2
< 50%	1
Clinical score ^b	
Excellent	18
Good	15, 16 or 17
Fair	13 or 14
Poor	< 13

^aExpressed as the percentage of the value obtained from the normal contralateral hip.

^bDetermined by adding the points for pain, walking and range of motion

Table 2. Matta's radiological criteria [19]

Grade	Osteophyte	Joint space narrowing	Sclerosis
Excellent	None	Normal	None
Good	Small	< 2 mm	Minimal
Fair	Moderate	< 50%	Moderate
Poor	Large	> 50%	Severe with femoral head collapse

3. RESULTS

The mean age of the patient was 37.96 year ranging from 20 - 60 years.

Males dominated in our study with M:F ratio of 7:3.

The Modified Postel Merle d'Aubigné score was used for calculation of clinical outcome of 30 patients. The results were excellent in 20 (66.6%), good in 8 (26.6%), fair in 2 (6.6%), and poor in 0 (0%) patients. On comparing the clinical outcome with type of fracture, the result showed significant difference with $p=0.049$ (Table 5, Fig. 3). The Joel Matta score was used for calculation of radiological outcome of 30 patients. The results were excellent in 19 (66.3%), good in 8 (26.6%), fair in 3 (10%), and poor in 0 (0%)

patients. On comparing the radiological outcome with type of fracture, the result showed significant difference with $p=0.037$ (Table 6, Fig. 5).

Table 3. Age incidence and distribution

Age	No of patients	Percentage
20 - 29 Years	8	26.66%
30 - 39 Years	10	33.33%
40 - 49 Years	7	23.33%
50 - 59 Years	5	16.66%

Table 4. Sex ratio

Sex	No of Patients	Percentage
Males	21	70%
Females	9	30%

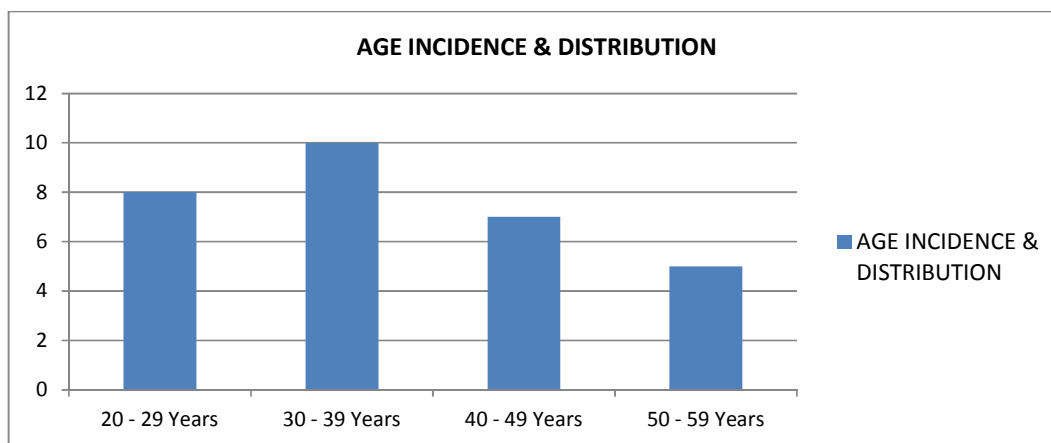


Fig. 1. Age incidence & distribution

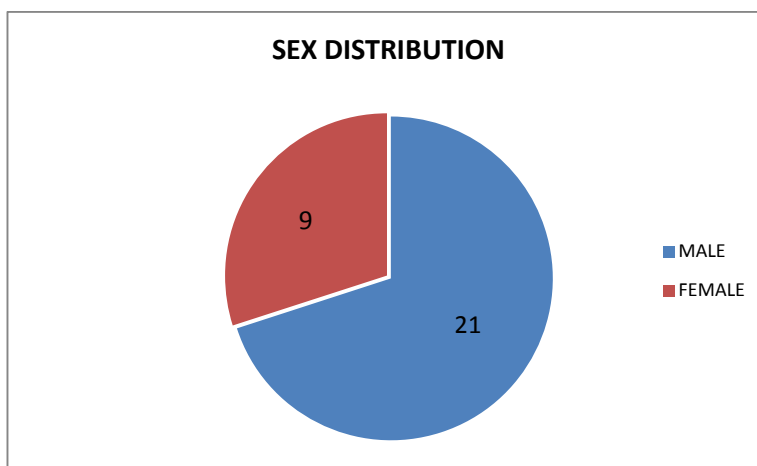


Fig. 2. Sex distribution

Table 5. Fracture distribution (N=30)

Fracture type (Judet & Letournel)	No of patients	Percentage
Posterior wall	8	26.66%
Transverse with Posterior wall	8	26.66%
Transverse	7	23.33%
Both column	7	23.33%

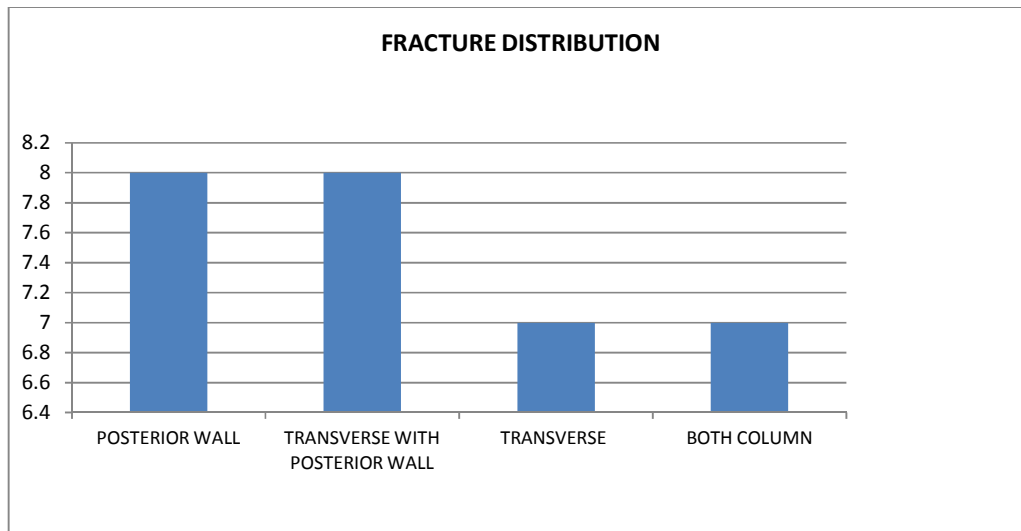


Fig. 3. Fracture distribution

Table 6. Comparison of clinical outcome with fracture type

Clinical outcome	Fracture type				Total
	Posterior wall	Transverse with posterior wall	Transverse	Both column	
Excellent	7 (87.5)	6 (75)	5 (71.4)	2 (28.6)	20 (66.6)
Good	0	1 (12.5)	2 (28.6)	5 (71.4)	8 (26.6)
Fair	1 (12.5)	1 (12.5)	0	0	2 (6.6)
Poor	0	0	0	0	0
Total	8 (100)	8 (100)	7 (100)	7 (100)	30 (100)
Chi sq	11.9		P value	0.049*	

*- significant ($p < 0.05$)

Table 7. Comparison of radiological outcome with Fracture type

Radiological outcome	Fracture type				Total
	Posterior wall	Transverse with posterior wall	Transverse	Both column	
Excellent	7 (87.5)	5 (62.5)	5 (71.4)	2 (28.6)	19 (63.3)
Good	0	1 (12.5)	2 (28.6)	5 (71.4)	8 (26.6)
Fair	1 (12.5)	2 (25)	0	0	3 (10)
Poor	0	0	0	0	0
Total	8 (100)	8 (100)	7 (100)	7 (100)	30 (100)
Chi sq	13.4		P value	0.037*	

*-Significant ($p < 0.05$)

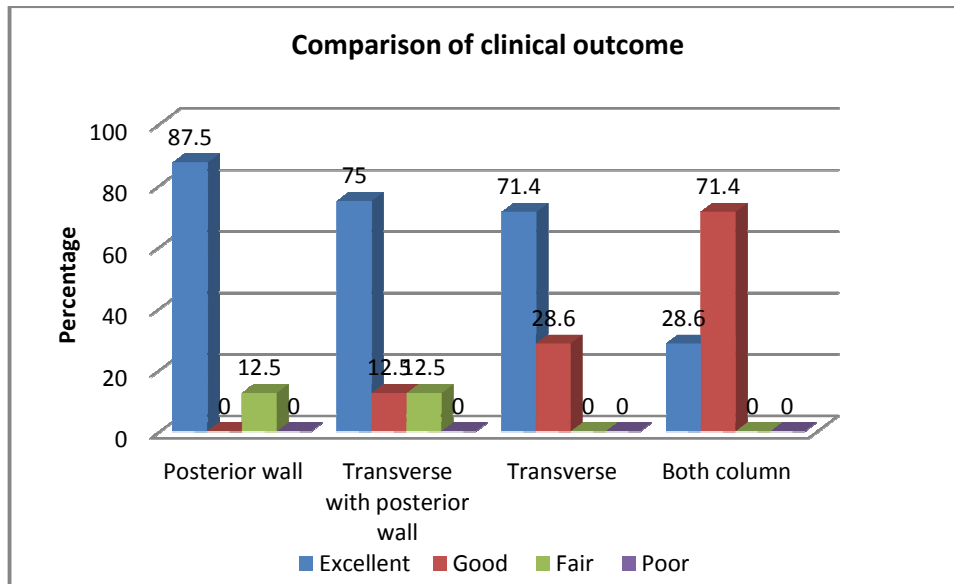


Fig. 4. Comparison of clinical outcome with Fracture type

Table 8. The details of Fracture Displacement, Clinical outcome and Radiological outcome

Fracture type	No of patients	Fracture displacement	Clinical outcome (Modified merle d'Aubinge postel score)	Radiological outcome (Joel Matta score)
Posterior wall	8	> 2 MM	Excellent - 7 Good - 0 Fair - 1 Poor - 0	Excellent - 7 Good - 0 Fair - 1 Poor - 0
Transverse with Posterior wall	8	> 2 MM	Excellent - 6 Good - 1 Fair - 1 Poor - 0	Excellent - 5 Good - 1 Fair - 2 Poor - 0
Transverse	7	> 2 MM	Excellent - 5 Good - 2 Fair - 0 Poor - 0	Excellent - 5 Good - 2 Fair - 0 Poor - 0
Both column	7	> 2 MM	Excellent - 2 Good - 5 Fair - 0 Poor - 0	Excellent - 2 Good - 5 Fair - 0 Poor - 0
Total Cases	30	> 2 MM	Excellent - 20 Good - 8 Fair - 2 Poor - 0	Excellent - 19 Good - 8 Fair - 3 Poor - 0

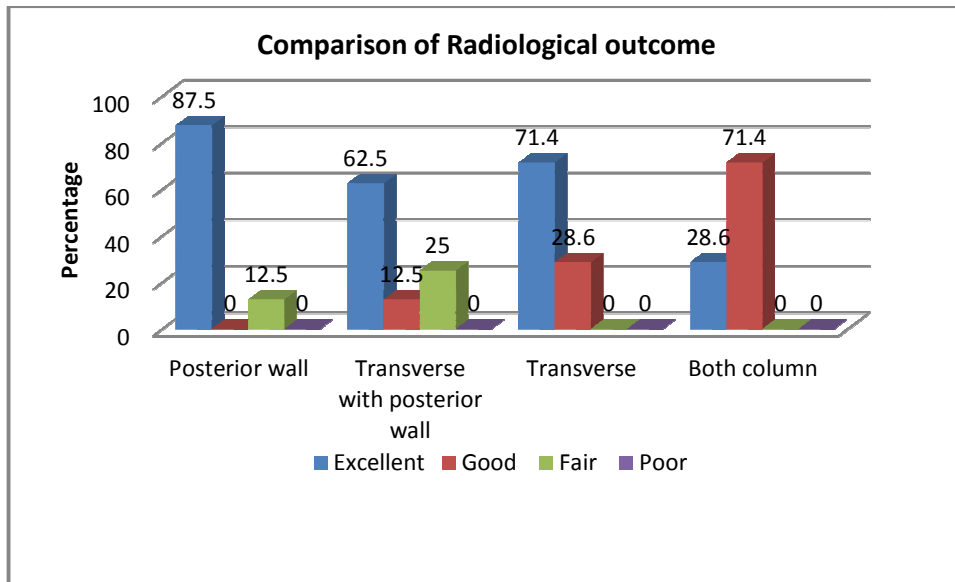


Fig. 5. Comparison of radiological outcome with Fracture type

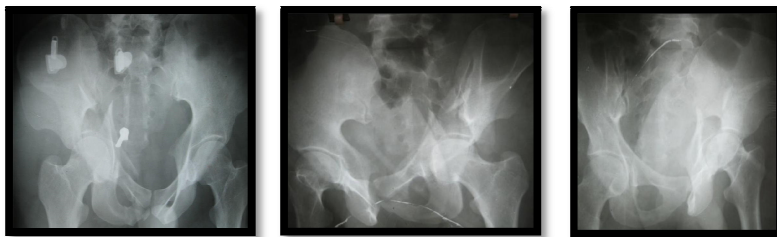

Fig. 6. Before surgery

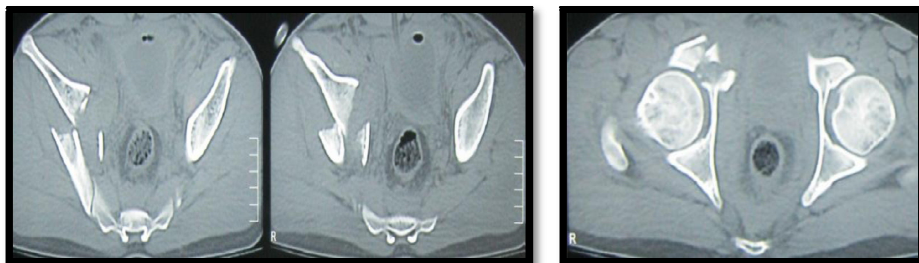


Fig. 7. CT scan

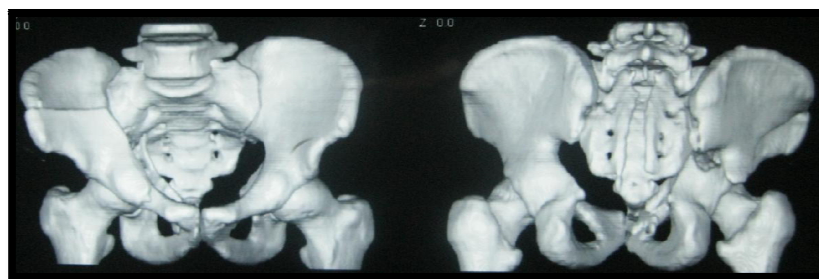


Fig. 8. 3D - CT scan

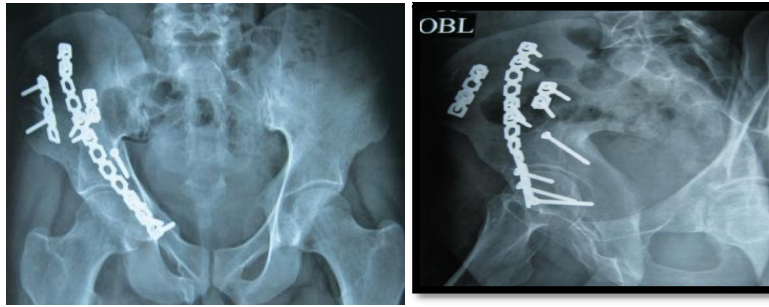


Fig. 9. At 1 year of follow-up

4. DISCUSSION

Management of acetabular fractures with displacement has made a severe impact in the outcome of patient mobilization to normal levels. In our study for a period of one year and six months, we assessed 30 cases with different fracture pattern of acetabulum. Acetabular fractures were classified as per Judet and Letournel classification. Clinical assessment was done by Modified merle d'aubinge and postel score. Radiological assessment done by Matta's criteria.

Upon evaluation of individual fracture pattern, Posterior wall type had radiologically 7 (87.5%) Excellent & 1 (12.5%) Fair and clinically 7 (87.5%) excellent & 1(12.5%) fair patients, Transverse with posterior wall type had radiologically 5 (62.5%) excellent, 1 (12.5%) good & 2 (25%) fair and clinically 6 (75%) excellent, 1 (12.5%) good & 1 (12.5%) fair patients, Transverse wall type had radiologically 5 (71.4%) excellent & 2 (28.6%) good and clinically 5 (71.4%) excellent & 2 (28.6%) good patients, Both Column type had radiologically 2 (28.6%) excellent & 5 (71.4%) good and clinically 2 (28.6%) excellent & 5 (71.4%) good patients respectively. Overall of 30 patients assessed, radiologically 19 (63.3%) patients were excellent, 8 (26.6%) patients were good & 3 (10%) patients were fair and clinically 20 (66.6%) patients were excellent, 8 (26.6%) were good & 2 (6.6%) patients were fair.

Frequency distribution of subjects according to the clinical outcome was done and Chi square was done to assess the significance. There is statistically significant difference in the outcomes with better outcomes in all the fracture patterns, (Chi sq value - 11.9, p = 0.049). Frequency distribution of subjects according to the radiological outcome was done and Chi square was done to assess the significance. There is

statistically significant difference in the outcomes with better outcomes in all the fracture patterns, (Chi sq value - 13.4, p = 0.037). Based upon the values obtained both clinically and radiologically, there was a significant p value of 0.049 clinically and 0.037 radiologically.

In the present study, congruency of the fracture site post-operatively has directly impact on the functional outcome. Those patients with fair results radiologically, had proportionately impacted the clinical outcome. However delay in rehabilitation, has also impacted the clinical outcome, because of the complex fracture pattern. Limitations in our study was small patient group, because of rarity of the cases and long-term follow-up will be a good predictor for the functional outcome.

5. CONCLUSION

Functional outcome of displaced acetabular fractures more than 2 mm displacement was found to have excellent results on open reduction and internal fixation. In our study, the excellent results for 30 patients were found to be clinically and radiologically significant. For a better outcome and better study, anatomical reduction and stable fixation presents a good outcome. Wherein, for a good study the number of patients needs to be in large number with a long-term follow-up to assess the functional outcome aptly.

CONSENT

Formal consent was taken from each patient pre-operatively and at each follow-up visit.

ETHICAL APPROVAL

As per international standard or university standard written ethical permission has been collected and preserved by the author(s).

COMPETING INTERESTS

Authors have declared that no competing interests exist.

REFERENCES

1. Negrin LL, Seligson D. Results of 167 consecutive cases of acetabular fractures using the Kocher-Langenbeck approach: A case series. *Journal of Orthopaedic Surgery and Research*. 2017;12(1):66.
2. Gupta RK, Singh H, Dev B, Kansay R, Gupta P, Garg S. Results of operative treatment of acetabular fractures from the Third World—how local factors affect the outcome. *International Orthopaedics*. 2009;33(2):347-52.
3. Magu NK, Rohilla R, Arora S. Conservatively treated acetabular fractures: A retrospective analysis. *Indian Journal of Orthopaedics*. 2012;46(1): 36.
4. Letournel E, Judet R. *Fractures of the acetabulum*, 2nd ed. New York NY: Springer – Verlag; 1993.
5. Matta JM. The accuracy of reduction and outcome of acetabular fractures. *J Bone Joint Surg [Am]*. 1996;78:1632-45.
6. Moed BR, Carr SEW, Watson JT. Results of the operative treatment of fractures of the posterior wall of the acetabulum. *J Orthop Trauma*. 2009;23:7-15.
7. Schreiner AJ, de Zwart PM, Stuby FM, Ochs BG. *Frakturendoprothetik des Azetabulums*. *OP-Journal*. 2016;32(03): 196-205.
8. James L. Guyton, Edward A. Perez. Fractures of acetabulum and pelvis. In Canale, Beaty & Azar: *Campbell's Operative Orthopaedics*; 13th ed. Elsevier. 2017;3:2865-2868.
9. Letournel E. Acetabular fractures classification and management. *Clin Orthop Relat Res*. 1984;151:81-106.
10. Borrelli J. Jr., Goldfarb C, Ricci W, Wagner JM, Engsborg JR. Functional outcome after isolated acetabular fractures. *Journal of Orthopaedic Trauma*. 2002;16(2):73-81.
11. Cole JD, Bolhofner BR. Acetabular fracture fixation via a modified Stoppa limited intrapelvic approach. Description of operative technique and preliminary treatment results. *Clinical Orthopaedics and Related Research*. 1994;305:112-23.
12. Giannoudis PV, Grotz MR, Papakostidis C, Dinopoulos H. Operative treatment of displaced fractures of the acetabulum: A meta-analysis. *The Journal of Bone and Joint Surgery*. 2005;87(1):2-9.
13. Starr AJ, Watson JT, Reinert CM, Jones AL, Whitlock S, Griffin DR, Borer DS. Complications following the “t extensile” approach: A modified extensile approach for acetabular fracture surgery—report of forty-three patients. *Journal of Orthopaedic Trauma*. 2002;16(8):535-42.
14. Judet R, Judet J, Letournel E. Fractures of the acetabulum: Classification and surgical approaches for open reduction preliminary report. *JBJS*. 1964;46(8):1615-75.
15. Matta JM, Anderson LM, Epstein HC, Hendricks P. Fractures of the acetabulum. A retrospective analysis. *Clinical Orthopaedics and Related Research*. 1986;205:230-40.
16. Parker PJ, Copeland C. Percutaneous fluoroscopic screw fixation of acetabular fractures. *Injury*. 1997;28(9-10):597-600.
17. Tile M, Helfet D, Kellam J, editors. *Fractures of the pelvis and acetabulum*. Lippincott Williams & Wilkins; 2003.
18. Moed BR, Carr SE, Gruson KI, Watson JT, Craig JG. Computed tomographic assessment of fractures of the posterior wall of the acetabulum after operative treatment. *JBJS*. 2003;85(3):512-22.
19. Matta JM. Operative treatment of acetabular fractures through the ilioinguinal approach: A 10-year perspective. *Journal of Orthopaedic Trauma*. 2006;20(1):S20-9.

© 2020 Pillella and John; This is an Open Access article distributed under the terms of the Creative Commons Attribution License (<http://creativecommons.org/licenses/by/4.0>), which permits unrestricted use, distribution, and reproduction in any medium, provided the original work is properly cited.

Peer-review history:

The peer review history for this paper can be accessed here:
<http://www.sdiarticle4.com/review-history/54216>