



Airway Management: A Case of Desmoplastic Ameloblastoma of Right Mandibular Body

**Deepjit Bhuyan^{a*‡}, Aruna V. Chandak^{b#}, Vijay Chandak^{b‡}, Sanjot Ninave^{b#}
and Neeta Verma^{b#}**

^a *Jawaharlal Nehru Medical College, DMIMS (DU), Sawangi (Meghe), Wardha, Maharashtra- 442001, India.*

^b *Department of Anaesthesiology, Jawaharlal Nehru Medical College, Datta Meghe Institute of Medical Science (DMIMS), India.*

Authors' contributions

This work was carried out in collaboration among all authors. All authors read and approved the final manuscript.

Article Information

DOI: 10.9734/JPRI/2021/v33i61A35762

Open Peer Review History:

This journal follows the Advanced Open Peer Review policy. Identity of the Reviewers, Editor(s) and additional Reviewers, peer review comments, different versions of the manuscript, comments of the editors, etc are available here: <https://www.sdiarticle5.com/review-history/82601>

Case Study

Received 20 October 2021
Accepted 27 December 2021
Published 28 December 2021

ABSTRACT

Background- Desmoplastic ameloblastoma (DA) is an uncommon variety of ameloblastoma that accounts for 4–13% of all cases, with notable differences in anatomical location, imaging, and histologic appearance. It is classified as a variety of ameloblastoma in the WHO classification of head and neck tumours (WHO-2005). Because it commonly occurs in the anterior region of the jaws as a mixed radio-opaque-radiolucent lesion, the tumour resembles a benign fibro-osseous lesion.

Case report- We present a case of desmoplastic ameloblastoma in a 51-year-old female with a painless swelling in the lower right region of mandible. Fine needle aspiration revealed no fluid. Both panoramic radiographs and a computed tomography scan revealed a mixed lesion with a multilocular appearance. Desmoplastic ameloblastoma was confirmed after an incisional biopsy. From teeth 41 to the angle of the jaw, a composite resection of the lesion was performed with segmental mandibulectomy. With a peek implant, it was repaired. The possibility for a problematic airway is emphasised in this case, with great surgical results.

[‡]MBBS, 3rd Year Resident Anesthesia;

[#]Professor;

[‡]Associate Professor;

*Corresponding author: E-mail: pooplibhuyan5@gmail.com;

Conclusion: Desmoplastic ameloblastoma is a kind of ameloblastoma with unique clinic radiographic and histologic characteristics. Despite its rarity, the tumour necessitates a thorough examination due to the challenges it poses with airway ventilation and intubation.

Keywords: Desmoplastic ameloblastoma; difficult intubation; airway; mandibulectomy; tumour.

1. INTRODUCTION

Ameloblastoma desmoplastica is a benign tumour that arises from the odontogenic epithelium and is divided into many histological forms. The odontogenic epithelium is the source of ameloblastoma, which is the second most frequent tumour after odontoma. Despite its locally invasive nature, the tumour is considered benign [1,2,3]. The most prevalent kinds of ameloblastoma are follicular and plexiform, followed by acanthomatous and granular cell types. Desmoplastic ameloblastoma, clear cell ameloblastoma, basal cell ameloblastoma, keratoameloblastoma, and unicystic ameloblastoma are less common cellular variations of ameloblastoma [4,5]. Despite this, due of the proclivity for recurrence and the likelihood of malignancy, this entity is classified as submalignant. A clinical, radiographic, and histological investigation is used to diagnose desmoplastic ameloblastoma. It is critical for effective therapy and timely case follow-up [6,7,8].

Desmoplastic ameloblastoma is distinct from other types of ameloblastoma in that it occurs more frequently in the anterior part of the jaw and has a mixed radiolucent radio-opaque look that is typically more reminiscent of a fibro-osseous lesion. The presence of large tumours in the oral and pharyngeal region is a predictor of a difficult airway [9,10-15].

2. CASE REPORT

A 51 year old female came to us with a painful swelling over the right lower region of the jaw. The swelling was progressive in nature and measured 7x4 centimeters. She denied any bleeding or changes in her senses. She also denied any previous trauma, and her medical, dental, and familial histories were irrelevant. She had also been having problems with mastication, deglutition, and breathing in the lying down posture for the past two years.

No signs of facial nerve involvement noted, no palpable cervical/axillary/external iliac/inguinal lymph nodes noted. Extraoral examination

revealed a large grossly asymmetrical swelling present over the lower right back region of jaw extending antero-posteriorly from the right corner of the mouth to 1 cm posterior to angle of the angle of mandible and superior-lateral from ala-tragus line to 2 cm below the lower border of the mandible. On palpation, tenderness absent, in duration present, consistency was firm. No evidence of bleeding or pus discharge present from it. The intra-oral examination revealed a swelling in the right mandibular region.

Preoperative investigation – (CBC) Hb – 10.8 gm%, WBC – 4000/cu.mm, Platelet count – 1.97lacs/cu.mm. Blood group and cross matching was done. Liver function test, kidney function test and thyroid function test were within normal limits.

The patient had orthopnea, (because the tumour was obstructing the upper airway) which meant she had trouble breathing in a lying down posture and needed to sleep with her head up or straight to keep her SPO₂ from dropping. Because the tumour was obstructing the upper airway, intubation using McCoy blades or video laryngoscope blades was expected to be challenging. As a result, the only choice was awake fibreoptic bronchoscopic intubation. The mouth opening was reduced (2 fingers) during the oral examination. Mallampatti grade was difficult to determine due to the presence of a tumour. She was nebulized with salbutamol and budesonide three times a day until surgery day, had chest physiotherapy, and her bedside PFT was normal. The patient's consent was obtained for invasive airway management, such as cricothyroidotomy, tracheotomy, and ventilator support.

Intravenous access of 18G was acquired in the preoperative room, and intravenous fluid of ringer lactate solution was started, nebulization with Loxicard 4 percent was performed, and injections of Atropine (0.01 mg/kg) and Promethazine (0.5 mg/kg) were given intramuscularly. The oxygen mask was worn the entire time. Emergency medications such as atropine, adrenaline, cardiovascular drugs, and bronchodilators were kept on hand, as well as a difficult airway cart.

During the pre-anaesthetic examination, anaesthesia consent was obtained. A fibreoptic intubation while awake was envisaged.

The patient was taken to the operating room, when multi-para monitors were installed (Heart Rate, ECG, Non-invasive Blood Pressure, Respiratory Rate, ETCO₂). Before awake fibre optic bronchoscopic intubation, the patient was kept in a head-up position and provided a shoulder ramp. A 7 mm cuffed flexometallic endotracheal tube was placed (left nasal) and tube placement confirmed using a fibreoptic bronchoscope, end tidal carbon dioxide graph, chest auscultation, and rising. Midazolam injections were administered throughout the process until the tube was inserted. Propofol (2 mg/kg) was administered after confirmation, followed by Vecuronium bromide (0.1 mg/kg) for muscular relaxation. The patient was maintained on O₂, sevoflurane and nitrous oxide. The ameloblastoma was surgically removed, and a peep implant was used to repair the area. The patient was reversed after surgery, and the likely plan was to leave the tube in place, but the patient could not tolerate it and was in extreme distress, so extubation was performed, with no post-extubation respiratory compromise detected.

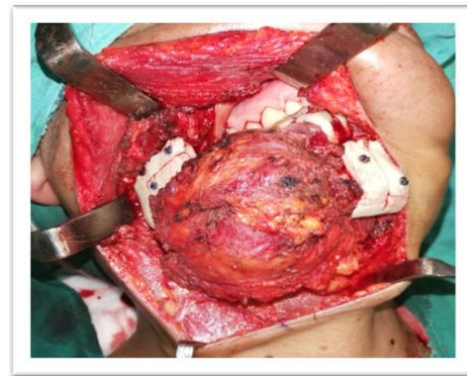


Fig. 3. Intraoperative

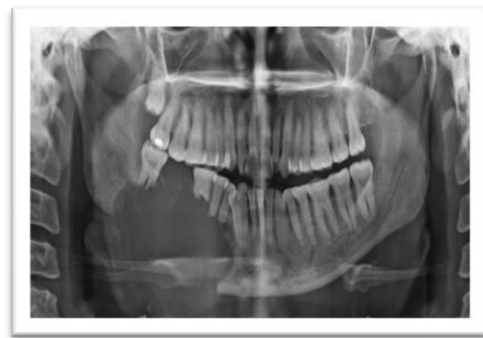

Fig. 4. Preoperative (Radiological)

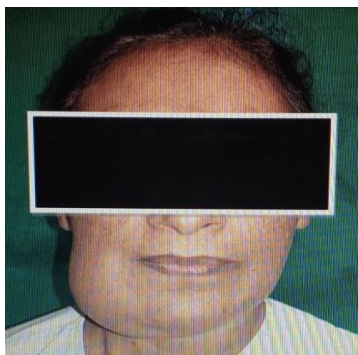


Fig. 1. Preoperatively

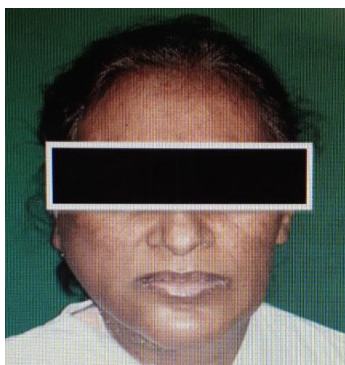

Fig. 2. Postoperatively

3. DISCUSSION

Expected airway difficulty should be examined and planned for prior to surgery, and if tracheal intubation fails, progressive care should be planned. Difficult airway equipment was stored on the cart, including all sizes of endotracheal tubes for suitable age and smaller, a fibre optic bronchoscope (FOB), a cricothyroid puncture set, tracheostomy tubes and set, and a breathing bougie. Nasal pretreatment with otrivin drops and lignocaine jelly 2 percent was done because awake intubation was planned. To be able to endure FOB, proper airway blocks must be administered. For airway blocks, a 2 percent – 2 ml of lignocaine was injected on either side of the neck. The greater cornua of the hyoid bone was palpated (below angle of mandible) and firm pressure was applied to displace it towards the side of block, a 25G needle was inserted to contact greater cornua of bone and then walked back and 2 ml was injected on each side. Inhalation with lignocaine 4 percent – 4 ml and trans-tracheal block were conducted by insertion of a needle into the cricothyroid membrane until resistance was eliminated (meant into larynx), aspiration, and injection of 4 percent – 4 ml of lignocaine.

Difficulties Faced during Intubation - The patient was intubated with a flexometallic endotracheal cuffed tube of number 7 mm. Due to the anticipated difficulty intubation as well as the significant risk of upper airway blockage due to tongue fall and depression of breathing, the patient was kept on light sedation.

The only guidance for the nasal ET tube was a small slit-like opening through which intubation was performed. Because a difficult airway was expected, all premedication was given in incremental doses, first intramuscularly and then with injection Glycopyrrolate (0.004 mg/kg) due to its maximum anti-sialagogue activity, and injection Midazolam (0.05 mg/kg) prior to reducing anxiety. Bilateral chest rise was detected after nasal intubation with a 7 mm cuffed flexometallic endotracheal tube, and air entry was examined, as well as the formation of an end tidal carbon dioxide graph, which was confirmed by fiberoptic bronchoscopy. The patient was given injection Fentanyl (1 mcg/kg), inducing agent – injection Propofol (2 mg/kg) and an intubating dose of muscle relaxant Vecuronium (0.1mg/kg). Patient was ventilated on volume control mode with Tidal Volume of 8 ml/kg, respiratory rate of 14/minute, positive end expiratory pressure (PEEP) of 5 cm H₂O, I:E ratio of 1:2, and maintained on O₂, N₂O, sevoflurane and vecuronium top-ups. The patient's vitals were unremarkable, analgesia was given with injection Fentanyl (1 mcg/kg) and later at the near end of surgery injection Paracetamol (15mg/kg). No complications were noted intraoperatively.

After the tumour was removed and the wound was closed, it was likely that the patient would be kept nasally intubated to avoid obstruction of the airway by the pharyngeal pouch, as the majority of tumours restrict the airway, making fiberoptic intubation problematic. However, because the patient was unable to tolerate the tube, extubation was performed under tight supervision with the use of a difficult airway trolley and an emergency tracheostomy set. There was no evidence of post-extubation respiratory impairment.

4. CONCLUSION

Despite the fact that desmoplastic ameloblastoma is a benign tumour, it requires careful examination not just for surgical excision but also for the airway ventilation and intubation problems it can cause. Prior to transferring the

patient to the operating room, caution must be exercised. The extent of the tumour, any compressive symptoms, and airway problems must all be ruled out prior to surgery. The placement and removal of a nasal endotracheal tube, as well as the monitoring of vital signs, must all be done intraoperatively. Following surgery, special precautions must be taken to avoid respiratory issues that could reflect the difficult airway.

DISCLAIMER

The products used for this research are commonly and predominantly use products in our area of research and country. There is absolutely no conflict of interest between the authors and producers of the products because we do not intend to use these products as an avenue for any litigation but for the advancement of knowledge. Also, the research was not funded by the producing company rather it was funded by personal efforts of the authors.

CONSENT

The patient's consent was obtained for invasive airway management, such as cricothyroidotomy, tracheotomy, and ventilator support.

ETHICAL APPROVAL

It is not applicable.

COMPETING INTERESTS

Authors have declared that no competing interests exist.

REFERENCES

1. Thompson IO, van Rensburg LJ, Phillips VM. Desmoplastic ameloblastoma: Correlative histopathology, radiology and CT-MR imaging. *J Oral Pathol Med.* 1996;25(7):405–10.
2. Barnes L, Eveson JW, Reichart P, Sidransky D, editors. *Pathology and genetics of head and neck tumours.* Lyon: IARC Press; 2005.
3. Nair PP, Bhat GR, Neelakantan S, Chatterjee R. Desmoplastic ameloblastoma of mandible. *BMJ Case Rep.* 2013;17(10):2013–200082.
4. Sheikh S, Pallagatti S, Singla I, Kalucha A. Desmoplastic ameloblastoma: A case report. *J Dent Res Dent*

- Clin Dent Prospects. 2011;5(1):27–32.
5. Effiom OA, Odukoya O. Desmoplastic ameloblastoma: Analysis of 17 Nigerian cases. *Oral Surg Oral Med Oral Pathol Oral Radiol Endod.* 2011;111(1):e27–31.
 6. Sivapathasundharam B, Einstein A, Syed RI. Desmoplastic ameloblastoma in Indians: report of five cases and review of literature. *Indian J Dent Res.* 2007;18(4):218–21.
 7. Cervelli D, Marianetti TM, Boniello R, Grussu F, Gasparini G, Azzuni C, et al. Giant neglected desmoplastic ameloblastoma: Reconstruction with free fibula flap. *J Craniofac Surg.* 2012;23(3):e171–4.
 8. Sharma G, Rao R, Talreja P, Pokle MB, Sawla R, Zope S. Case report of patient with desmoplastic ameloblastoma. *IJCRR.* 2014;6(10):37–44.
 9. Sun ZJ, Wu YR, Cheng N, Zwahlen RA, Zhao YF. Desmoplastic ameloblastoma—a review. *Oral Oncol.* 2009;45(9):752–9.
 10. Savithri V, Janardhanan M, Suresh R, Kumar RBV. Desmoplastic ameloblastoma with osteoplasia: review of literature with a case report. *J Oral Maxillofac Pathol.* 2013;17(2):298–301.
 11. Ahmad I, El-Boghdadly K, Bhagrath R. Difficult Airway Society guidelines for awake tracheal intubation (ATI) in adults. *Anaesthesia.* 2020;75:509-528.
 12. Oteri G, Lentini M, Pisano M, Cicciù M. Peripheral desmoplastic ameloblastoma in adolescent age: Clinico-pathological and immunohistochemical analysis of a case. *Open Dentistry J.* 2014;8:159–63.
 13. Aher DVB, Chaudhary DSY, Birangane DRS. Desmoplastic ameloblastoma: case report and review. *SEAJCRR.* 2015;4(4):1866–75.
 14. Ithomy M, Ramadan E, Curran E, Walsh S.R. Videolaryngoscopy vs. fiberoptic bronchoscopy for awake tracheal intubation: A systematic review and meta-analysis. *Anaesthesia.* 2018;73:1151-1161.
 15. Van Zundert AA, Endlich Y, Beckmann LA, et al. 2021 Update on airway management from the Anaesthesia Continuing Education Airway Management Special Interest Group. *Anaesthesia and Intensive Care.* 2021;49(4):257-267.

© 2021 Bhuyan et al.; This is an Open Access article distributed under the terms of the Creative Commons Attribution License (<http://creativecommons.org/licenses/by/4.0>), which permits unrestricted use, distribution, and reproduction in any medium, provided the original work is properly cited.

Peer-review history:

The peer review history for this paper can be accessed here:
<https://www.sdiarticle5.com/review-history/82601>