



Calciphylaxis in Hemodialysis Patients: Diagnosis and Treatment about a Case

S. Hamine ^{a*}, N. Jouan ^a, D. Dahmane ^a and P. Grimbert ^a

^a Department of Nephrology and Dialysis, University Hospital Cente Henri Mondor Créteil, France.

Authors' contributions

This work was carried out in collaboration among all authors. All authors read and approved the final manuscript.

Article Information

Open Peer Review History:

This journal follows the Advanced Open Peer Review policy. Identity of the Reviewers, Editor(s) and additional Reviewers, peer review comments, different versions of the manuscript, comments of the editors, etc are available here: <https://www.sdiarticle5.com/review-history/99430>

Case Study

Received: 08/03/2023
Accepted: 11/05/2023
Published: 20/05/2023

ABSTRACT

Calciphylaxis is a condition that causes cutaneous necrosis, which primarily affects patients with end-stage renal disease undergoing dialysis. Histologically, this condition is characterized by subintimal calcific deposits in small-caliber arteries, leading to luminal obstruction. Unlike medial calcification, which affects the media of arteries, calciphylaxis affects the intima of arterioles. Early diagnosis and appropriate management, including addressing the underlying cause, can improve the poor prognosis associated with this condition.

In this case report, a 59-year-old woman with end-stage diabetic nephropathy and chronic kidney disease on hemodialysis presented with large, painful, ulcerated lesions on the inner aspects of both knees that were shallow and showed no signs of bacterial superinfection. Hypercalcemia was noted on biochemical analysis, and radiographs of the thighs revealed vascular calcifications of the superficial femoral, popliteal, and leg arteries bilaterally. Histological examination revealed dermal neovascularization with stasis thrombi and secondary epidermal necrosis, indicating an underlying thromboembolic phenomenon. The management consisted of analgesic treatment and daily local care, along with intensified dialysis sessions with sodium thiosulfate and rheopheresis. A marked improvement in the patient's condition was observed following an accidental occurrence of resolving gas embolism after hyperbaric oxygen therapy, which played a significant role in the regression of cutaneous necrosis.

Therefore, hyperbaric oxygenation may be considered as a potential treatment option for calciphylaxis.

*Corresponding author: E-mail: Salmahamine@gmail.com;

Keywords: Calciphylaxis; hemodialysis; renal disease; calcific deposits.

1. INTRODUCTION

Calciphylaxis is a rare and severe pathology that affects patients with end-stage chronic kidney disease. It is a phenomenon of ischemic, cutaneous, and sometimes systemic necrosis due to the obliteration of arterioles first by subintimal calcium deposits and then by thrombosis [1]. It evolves in the context of primary hyperparathyroidism, anticoagulant therapy, or neoplasia. We report a case of uremic calciphylaxis in the context of end-stage renal failure.

2. CASE REPORT

A 59-year-old woman, followed for end-stage chronic kidney disease on hemodialysis due to diabetic nephropathy since September 2021, with a history of ischemic stroke complicating an embolic cardiopathy on oral anticoagulant, hypertension, type 2 diabetes, and morbid obesity (BMI=46.8), presented since July 2022 large, painful, ulcerated, lividoid, fibrinous lesions with deep secondary induration and necrosis on the lateral aspects of both thighs, without bone contact, and involvement of the inner aspects of the knees, less deep, without signs of bacterial superinfection (Fig. 1).

Laboratory results revealed hypercalcemia at 2.74 mmol/l, normal phosphatemia at 0.55 mmol/l, and hyperparathyroidism at 11 times the normal range. Radiography of the thighs showed vascular calcifications of the superficial femoral, popliteal, and tibial arteries bilaterally, without notable abnormality of the bone structure (Fig. 1). Histology did not show lesions of calciphylaxis on two skin biopsies with one-month interval; the first biopsy showed dermal neoangiogenesis with stagnant thrombi and secondary epidermal necrosis, suggestive of an underlying thromboembolic phenomenon, which was also found in the second biopsy, with the presence of hypodermal ischemic necrosis areas and fibrin-ruoric thrombi of small hypodermal capillaries whose primitive or secondary nature was difficult to determine. Even in the absence of characteristic calciphylaxis lesions on histology, the diagnosis of calciphylaxis was established based on the typical clinical and biological presentation, and confirmed retrospectively after improvement under treatment.

The initial management consisted of local care using hydrocellular dressings and Algosteril,

treatment with sodium thiosulfate 25 mg three times per week during dialysis, and correction of hyperparathyroidism with calcimimetics, but after one month, the patient's pain worsened, and there was no improvement in the skin lesions. The patient was then hospitalized in the dermatology department and continued hemodialysis in our unit. Secondary management consisted of analgesic treatment and daily local care with mechanical debridement of fibrin and Algosteril packing with secondary hydrocellular dressing. Hemodialysis was intensified from 3 to 6 times per week, with intravenous sodium thiosulfate 25 mg three times per week and rheopheresis treatment twice per week during the first two weeks and once per week during maintenance phase, with a total of eight sessions. We also stopped the oral anticoagulant as a contributing factor to calciphylaxis and due to the increased risk of bleeding associated with rheopheresis. Additionally, the patient presented a resolving gas embolism after hyperbaric oxygen therapy, which also partially resolved the skin necrosis. The patient's condition improved, with healing of the skin lesions and regression of pain.

3. DISCUSSION

The physiopathology of calciphylaxis has not yet been fully elucidated. It appears that the calcification of cutaneous arterioles is the first step and necessary condition for the subsequent development of necrosis. Contrary to what has been thought for a long time, calcification does not occur solely due to an increase in the phosphocalcic product, which, reaching a critical threshold, would allow the formation of crystals [2]. Indeed, in the physiological state, the value of the phosphocalcic product may be sufficient for this to occur. Therefore, this is only one of the factors involved, albeit one of the most important [3]. In recent years, numerous studies have highlighted some of the mechanisms associated with calcification: a decrease in the quantity of inhibitory molecules, transformation of media myocytes into bone-like cells, release of calcium crystals by increased bone resorption, cell death, and vitamin D supplementation [4].

Calciphylaxis is a rare and severe pathology that affects patients with end-stage chronic kidney disease. It is a pathology of the dermal and subdermal microvessels that become calcified and whose thrombosis leads to cutaneous

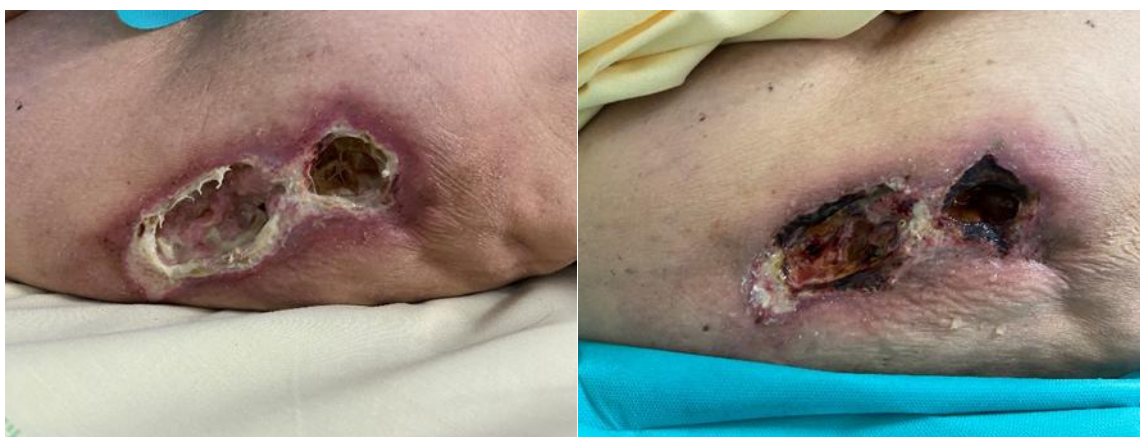


Fig. 1. Ulcerated, lividoid, fibrinous lesions with induration and necrosis of the thigh

necrosis. Calciphylaxis lesions can be distal and axial, causing intense pain, infections, and high mortality rates (40-80% at 1 year) [5]. The pathophysiology is based on mineral and bone abnormalities of CKD [6] and the major role of vitamin K antagonists (VKAs) in the formation of arteriolar microcalcifications in calciphylaxis [7,8]. Its prognosis remains grim, with a mortality rate at 1 year ranging from 40 to 80% [9].

The clinical presentation is characterized by hyperalgesic and indurated lesions. Initially appearing atonic with lividoid periphery, in a geographical pattern, they evolve into necrosis. The development of vascular microcalcifications is secondary to an imbalance between inducing and neutralizing factors of calcification associated with a change in phenotype of smooth muscle cells [10].

Correction of risk factors, optimization of dialysis, wound care, and pain management should be systematic for all patients with calciphylaxis. Sodium thiosulfate treatment, which is an antioxidant agent, acts by chelating calcium and attenuating prothrombotic endothelial dysfunction induced by oxidative stress. Retrospective small series have reported a beneficial effect of hyperbaric oxygen therapy in this indication [11], which is consistent with the result of our case, demonstrating an improvement in lesions after hyperbaric oxygenation, making it an effective treatment for calciphylaxis.

4. CONCLUSION

Calciphylaxis remains a rare but serious complication of end-stage chronic kidney disease requiring multidisciplinary management. Early diagnosis allows for rapid and appropriate

management. The beneficial effect of hyperbaric oxygenation can be considered as a systematic treatment for calciphylaxis.

CONSENT

As per international standard or university standard, patient(s) written consent has been collected and preserved by the author(s).

ETHICAL APPROVAL

As per international standard or university standard written ethical approval has been collected and preserved by the author(s).

COMPETING INTERESTS

Authors have declared that no competing interests exist.

REFERENCES

1. Duval A, Moranne O, Vanhille P, Hachulla E, Delaporte E. Artériopathie calcique (calciphylaxie) calcic arteriopathie (calciphylaxis). *La Revue de Médecine Interne*. 2006;27(3):184-195.
2. Au S, Crawford RI. Three-dimensional analysis of a calciphylaxis plaque: Clues to pathogenesis. *J Am Acad Dermatol*. 2002;47(1):53-7.
3. Agharbi FZ, et al. Uremic calciphylaxis: About two cases. *Pan African Medical Journal*; 2020.
4. Speer MY, Giachelli CM. Regulation of cardiovascular calcification. *Cardiovasc Pathol*. 2004;13(2):63-70.
5. Zabinnyk A, et al. Un nouvel agent anti-cristallisation, inhibe la calcification induite

- dans un modèle in vitro de calcification de la valve aortique humaine. *Vascul Pharmacol*; 2019.
6. Baldwin C, et al. Prise en charge multi-interventionnelle de la calciphylaxie: A propos de 7 cas. *Suis J Kidney Dis*; 2011.
 7. Ellis CL, et al. Spécificité discutable des résultats histologiques dans l'artériopathie urémique calcifiante. *Rein Int*; 2018.
 8. Chen NX, et al. La calcification artérielle induite par les adipocytes est prévenue grâce au thiosulfate de sodium. *Biochem Biophys Res Commun*; 2014.
 9. Gabel CK, et al. Assessment of outcomes of calciphylaxis *J Am Acad Dermatol*; 2021.
 10. Cassius C, et al. Calciphylaxis in haemodialysed patients : diagnostic value of calcifications in cutaneous biopsy *Br J Dermatol*; 2018.
 11. Basile C, et al. Hyperbaric oxygen therapy for calcific uremic arteriopathy: A case series. *J Nephrol*; 2002.

© 2023 Hamine et al.; This is an Open Access article distributed under the terms of the Creative Commons Attribution License (<http://creativecommons.org/licenses/by/4.0>), which permits unrestricted use, distribution, and reproduction in any medium, provided the original work is properly cited.

Peer-review history:

The peer review history for this paper can be accessed here:
<https://www.sdiarticle5.com/review-history/99430>