

Feasibility of Complete Aortic Valve Cusp Replacement Using CardioCel® in Early Childhood

**Robert Wagner^{1*}, Marcel Vollroth^{2*}, Jaroslav Benedik³, Ingo Daehnert¹
and Martin Kostelka²**

¹*Department of Pediatric Cardiology, University of Leipzig, Heart Center, Leipzig, Germany.*

²*Department of Cardiac Surgery, University of Leipzig, Heart Center, Leipzig, Germany.*

³*West German Heart and Vascular Centre, Department of Thoracic and Cardiovascular Surgery, University Hospital Essen, Essen, Germany.*

Authors' contributions

This work was carried out in collaboration between all authors. Authors RW and MV contributed equally. All authors read and approved the final manuscript.

Article Information

DOI: 10.9734/CA/2018/39130

Editor(s):

(1) Jagadeesh Kalavakunta, Assistant Professor, Medicine, cardiology Department, Michigan State University, Michigan and Homer Stryker M. D. School of Medicine, Western Michigan University, Michigan.

Reviewers:

(1) Damyanti Agrawal, Banaras Hindu University, India.

(2) Masaki Hamamoto, JA Hiroshima General Hospital, Japan.

(3) Youri Chesnov, Belarus.

Complete Peer review History: <http://www.sciencedomain.org/review-history/23073>

Case Study

Received 25th November 2017
Accepted 1st February 2018
Published 8th February 2018

ABSTRACT

The presented case is the report on a successful complete aortic valve cusp replacement using tissue-engineered xenogenic CardioCel® material in early childhood.

Keywords: *Congenital aortic regurgitation; balloon valvuloplasty; aortic valve reconstruction; cusp replacement; CardioCel®.*

1. INTRODUCTION

We present a case of a 4-year-old girl with successful surgical treatment of a symptomatic high-grade aortic valve regurgitation following balloon valvuloplasty for neonatal critical aortic stenosis that illustrates feasibility of complete

aortic valve cusp replacement in early childhood in selected patients.

2. PRESENTATION OF CASE

In the neonatal period, the girl had to undergo interventional balloon valvuloplasty for neonatal

*Corresponding author: E-mail: robert.wagner@medizin.uni-leipzig.de;

critical aortic stenosis. Initially, stenosis was relieved and insufficiency was mild. Unfortunately, aortic valve insufficiency progressed to high-grade (Fig. 1) and symptomatic in the following years with signs of left ventricular enlargement and dysfunction.

Therefore, we opted for an aortic valve reconstruction procedure at the age of four years. After resection of the severely destructed valve, we decided for a pair of neo-cusps using 'superlast AV-cusp gauges' as templates with sizes of 20x25 mm (MVB-1) and 22x28 mm (MVB-2, FEHLING INSTRUMENTS, Karlstein, Germany) (Fig. 2).

The sizing and implanting technique was adopted from the Ozaki's procedure using 5-0

monofilament running sutures into the slightly enlarged aortic annulus and bulb (Fig. 3).

We used tissue-engineered bovine pericardium CardioCel® (Admedus, Perth, Australia) for the aortic valve leaflet replacement. The early postoperative course was uneventful. The valve's shape appeared in a typical manner with elongated cusps which showed no stenosis and allowed valve competence (Fig. 4).

After full recovery valve competence was confirmed again and appeared even stable at a 12-month-follow-up without any other treatment (Fig. 5).

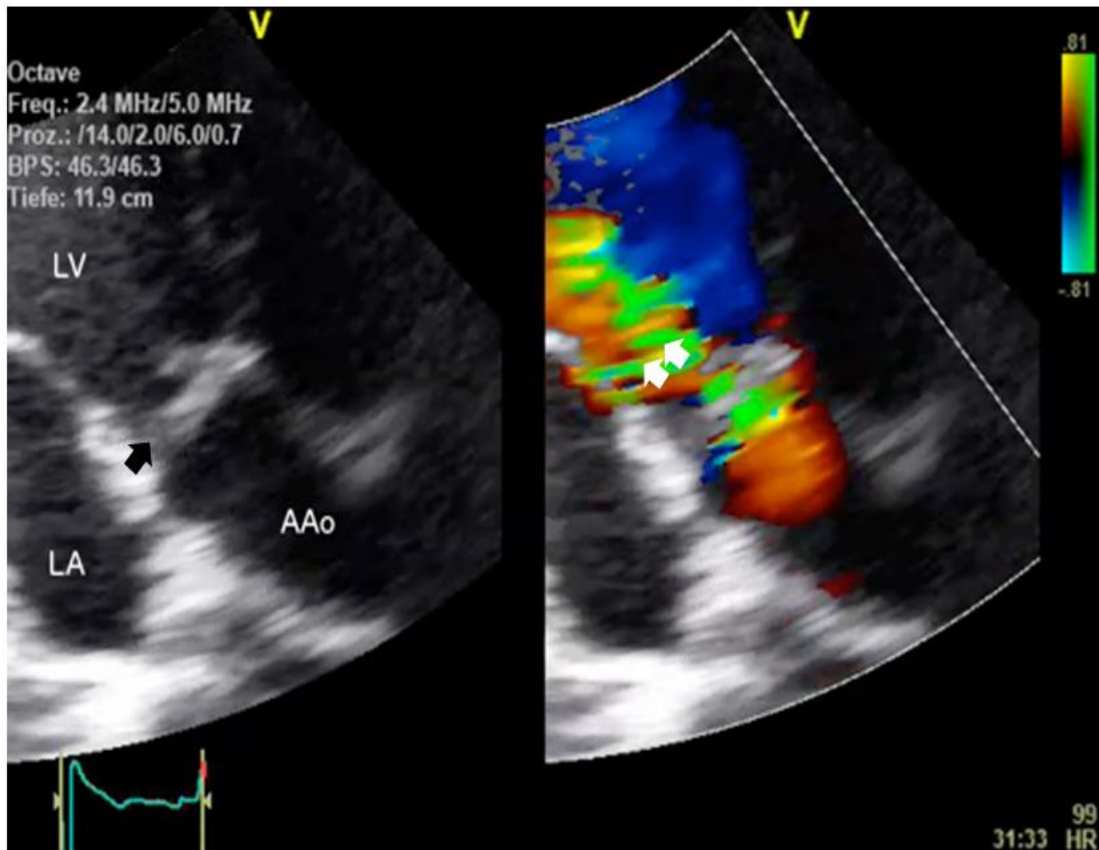


Fig. 1. High-grade aortic regurgitation in transthoracic echocardiography

Transthoracic echocardiography (apical 3 chamber view focused on the left ventricular outflow tract) confirmed progressive high-grade aortic regurgitation) following balloon angioplasty of a congenital critical stenosis of a bicuspid aortic valve (LA = left atrium, LV = left ventricle, AAo = ascending aorta, → closed aortic valve in late diastole, →→ regurgitant jet directed to the anterior mitral leaflet)




Fig. 2. Neo-cusps templates

'Superlast AV-cusp gauges' with sizes of 20x25mm (MVB-1) and 22x28mm (MVB-2, FEHLING INSTRUMENTS, Karlstein, Germany) on the right

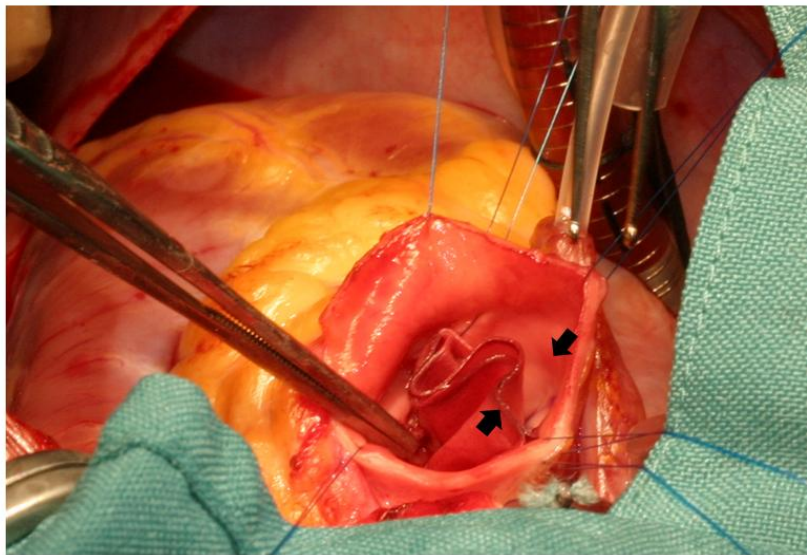


Fig. 3. Intraoperative situs

Intraoperative situs: transected aorta with a pair of CardioCel® neo-cusps (→←) placed into the corresponding aortic sinus

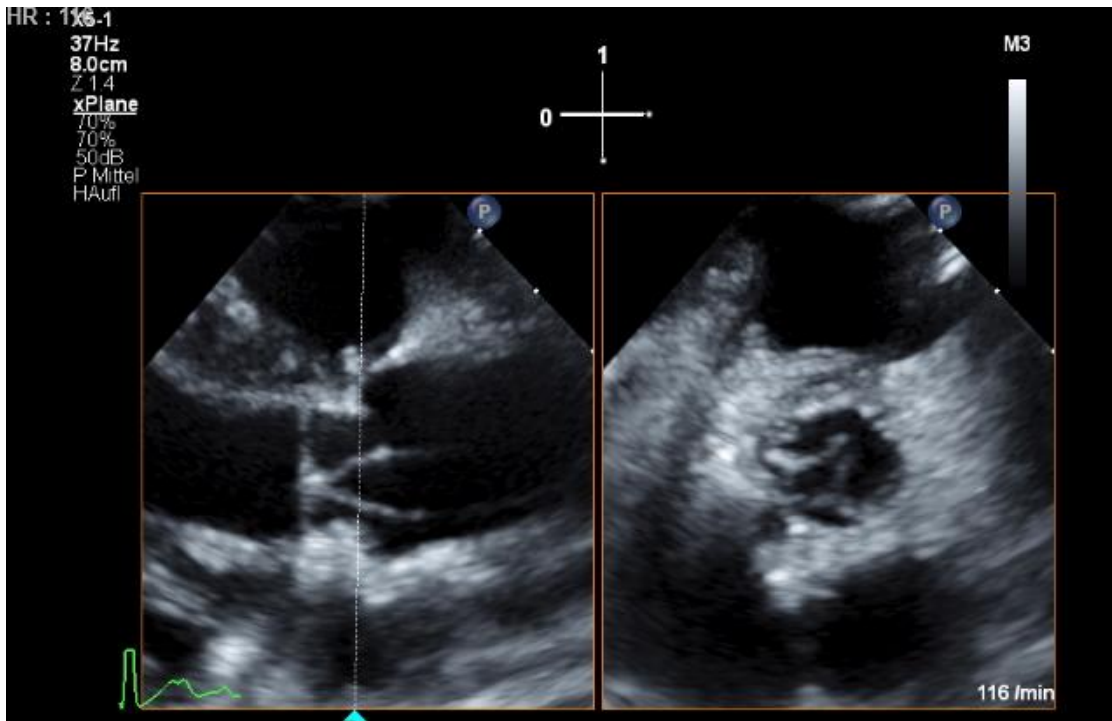


Fig. 4. Early postoperative biplane transthoracic echocardiography

Biplane transthoracic echocardiography showed the typical valve shape with deep coaptation following Ozaki's procedure for aortic valve cusp replacement (parasternal long and short axis)

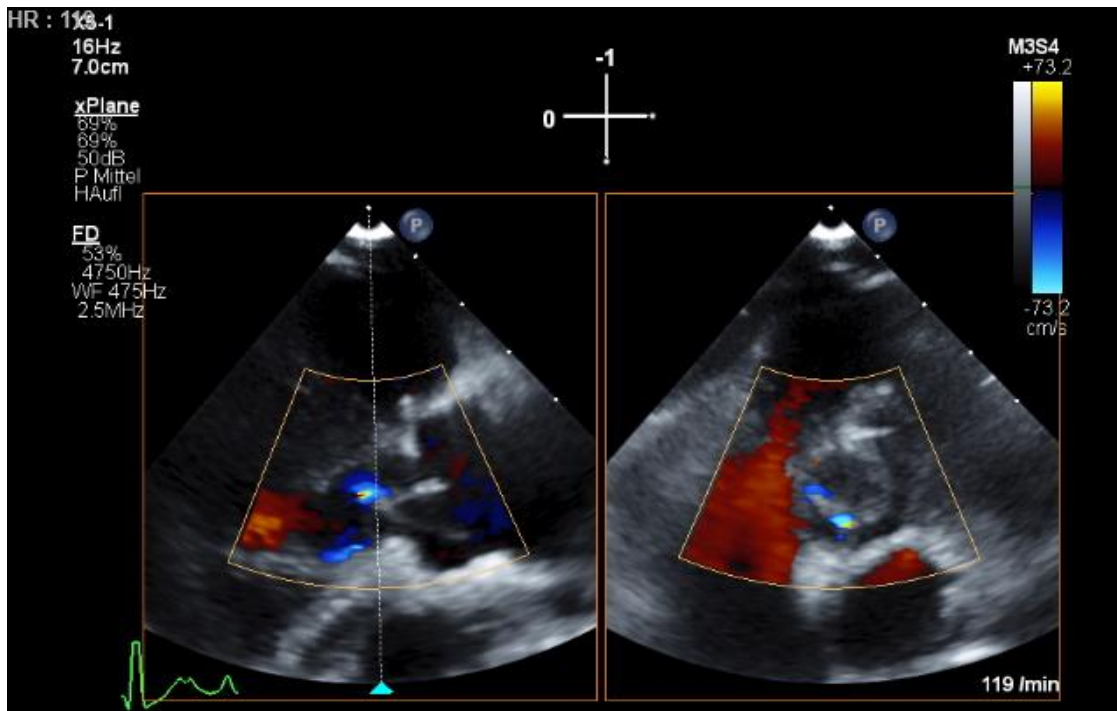


Fig. 5. Biplane color flow transthoracic echocardiography in the follow-up

Color flow echocardiography demonstrated irrelevant central neo valve regurgitation (parasternal long and short axis)

3. DISCUSSION

Nowadays, effective interventional treatment of critical neonatal aortic stenosis has become common practice in pediatric cardiology [1]. Favorable early consecutive mild insufficiency could progress to significant high-grade and symptomatic aortic regurgitation over time. Commissural fusion, variable leaflet dysplasia and extensive balloon tearing contribute to these issues and presentation in early childhood. In fact, this leaflet disease limits native valve repair techniques such as leaflet shaping or extension using autologous pericardium [2,3]. Techniques which go along with aortic valve replacement e.g. prosthetic valve replacement with tissue valves, mechanical valves or the Ross procedure bear different but often clinical relevant problems in early childhood (fixing of annular diameter, requirement of therapeutic anticoagulation, prosthesis-patient mismatch due to out-growing). Therefore, aortic valve repair is an attractive option, but results have been variable due to above mentioned reasons. Complete replacement of the aortic valve leaflets using autologous pericardium was shown to be 'possible with improved understanding of required leaflet geometry and better implant techniques' [4–6]. The template-adapted new leaflet tissue is sewn into the aortic annulus which enhances mobility of the pericardial leaflets with minimal gradients and regurgitation fractions [4]. It is even an option in cases of smaller aortic roots and could lower the risk of suture disruption compared to native leaflet repair [6]. Mazitelli et al. introduced the use of tissue-engineered pericardium (CardioCel®) for this purpose [6]. This industrially tissue-engineered, multistep fixed and processed xenogenic tissue is approved by the Food and Drug Administration and received the CE Mark in 2013. As the tissue is available of "off-the-shelf", it is of consistent quality with mechanical properties comparable to aortic valve tissue, but with stronger tissue strength [6]. Time consuming Glutaraldehyde fixation of autologous pericardium at the operating table become unnecessary. Information indicates that CardioCel® allows autologous tissue ingrowth and thus converting it to host-compatible tissue [7]. Long-term follow-up data for indications of valve leaflet replacement with this tissue is currently not available. In the presented case of a 4-year old girl with complete aortic valve cusp replacement with a pair of CardioCel® neo-cusps was an effective procedure with consistent valve competency even in the 1-year-follow-up.

4. CONCLUSION

To the authors knowledge this case represents the youngest patient who successfully underwent surgical treatment of a symptomatic high grade aortic valve with complete aortic valve cusp replacement using tissue-engineered xenogenic CardioCel® material. The authors opted for reconstruction of the aortic valve rather than replacing it because of potential problems such as the need for anticoagulation or prosthesis out-grow. Nevertheless, the child's further clinical course regarding sufficient valve function and the adaption of the technique to a larger series of comparable patients will indicate the long-term effectiveness of the treatment with this approach in early childhood ('time will tell').

CONSENT

The patient's parents have given their informed consent for the case report to be published.

ETHICAL APPROVAL

Since the report is a case presentation formal ethics approval is not applicable. The report has been conducted in accordance with the ethical standards laid down in the 1964 Declaration of Helsinki.

COMPETING INTERESTS

Authors have declared that no competing interests exist.

REFERENCES

1. Ewert P, Bertram H, Breuer J, Dähnert I, Dittrich S, Eicken A, et al. Balloon valvuloplasty in the treatment of congenital aortic valve stenosis—a retrospective multicenter survey of more than 1000 patients. *Int J Cardiol.* 2011;149(2):182–5. DOI: 10.1016/j.ijcard.2010.01.005
PID: 20153064.
2. d'Udekem Y. Aortic valve surgery in children. *Heart.* 2011;97(14):1182–9. DOI: 10.1136/hrt.2009.190520
PID: 21685483.
3. De La Zerda, David J, Cohen O, Fishbein MC, Odim J, A Calderon C, Hekmat D, et al. Aortic valve-sparing repair with autologous pericardial leaflet extension has a greater early re-operation rate in congenital versus acquired valve disease. *Eur J Cardiothorac Surg.* 2007;31(2):256–60.

- DOI: 10.1016/j.ejcts.2006.11.027
PID: 17196393.
4. Ozaki S, Kawase I, Yamashita H, Uchida S, Nozawa Y, Takatoh M, Hagiwara S. A total of 404 cases of aortic valve reconstruction with glutaraldehyde-treated autologous pericardium. *J Thorac Cardiovasc Surg.* 2014;147(1):301–6.
DOI: 10.1016/j.jtcvs.2012.11.012
PID: 23228404.
5. Rankin JS, Nöbauer C, Crooke PS, Schreiber C, Lange R, Mazzitelli D. Techniques of autologous pericardial leaflet replacement for aortic valve reconstruction. *Ann Thorac Surg.* 2014; 98(2):743–5.
DOI: 10.1016/j.athoracsur.2013.11.086
PID: 25087813.
6. Mazzitelli D, Nöbauer C, Rankin JS, Vogt M, Lange R, Schreiber C. Complete aortic valve cusp replacement in the pediatric population using tissue-engineered bovine pericardium. *Ann Thorac Surg.* 2015; 100(5):1923–5.
DOI: 10.1016/j.athoracsur.2015.04.056
PID: 26522549.
7. Neethling WML, Strange G, Firth L, Smit FE. Evaluation of a tissue-engineered bovine pericardial patch in paediatric patients with congenital cardiac anomalies: initial experience with the ADAPT-treated CardioCel(R) patch. *Interact Cardiovasc Thorac Surg.* 2013;17(4):698–702.
DOI: 10.1093/icvts/ivt268
PID 23832918.

APPENDIX

appendix_loop1_early_ozaki_praeop.avi



appendix_loop1_early_ozaki_praeop.avi

Loop 1: High-grade aortic regurgitation following balloon angioplasty of a congenital critical stenosis before repair.

appendix_loop2_early_ozaki_post_cfm.avi



appendix_loop2_early_ozaki_post_cfm.avi

Loop 2: Biplane color flow echocardiography demonstrating irrelevant central neo valve insufficiency and no relevant stenosis after repair.

© 2018 Wagner et al.; This is an Open Access article distributed under the terms of the Creative Commons Attribution License (<http://creativecommons.org/licenses/by/4.0>), which permits unrestricted use, distribution, and reproduction in any medium, provided the original work is properly cited.

Peer-review history:
The peer review history for this paper can be accessed here:
<http://www.sciencedomain.org/review-history/23073>